IEJ Iranian Endodontic Journal

Canal Transportation and Centering after Using PathFile and R-Pilot in Mesiobuccal Canals of Maxillary Molars Using Cone-Beam Computed Tomography

Kiumars Nazari Moghadam[a*], Somaye Teimoori[b], Hossein Labbaf[a], Ali Kazemi[a], Ali Kavosi[c], Fateme Mahdavi[d]

[a] Department of Endodontics, , School of Dentistry, Shahed University, Tehran, Iran; [b] Department of Endodontics, School of Dentistry, Semnan university, Semnan, Iran; [c] Department of Oral and Maxillofacial Radiology, School of Dentistry, Shahed University, Tehran, Iran; [d] School of Dentistry, Shahed University, Tehran, Iran

ARTICLE INFO

Article Type:
Original Article

Received: 13 Apr 2018
Revised: 01 Aug 2018
Accepted: 15 Aug 2018
Doi: *10.22037/iej.v14i1.21601*

**Corresponding author*: Kiumars Nazari Moghadam, Department of Endodontics, Dental School, Shahed University, Tehran, Iran.

Tel: +98-912 3939668
E-mail: naz819kiuma@gmail.com

ABSTRACT

Introduction: This study aimed to compare the changes in root canal anatomy following the use of PathFile and R-Pilot using cone-beam computed tomography (CBCT). **Methods and Materials:** In this *in vitro*, experimental study, 60 extracted maxillary first and second molars with 20 to 40° mesiobuccal root curvature, minimum of 19 mm of root length, no calcified root canals and no history of previous treatment were divided into two groups (n=30). CBCT scans were taken before and after the treatment, and sections at 1, 2 and 3 mm from the apex were compared. Pairwise comparisons were carried out using the Mann Whitney-U test. The centering ratio data were analyzed using the *Chi*-square test and Fisher's exact test. All statistical analyses were carried out using Sigma Stat 4 software. **Results:** The difference between PathFile and R-Pilot in canal transportation in mesiodistal direction was significant at 1 and 2 mm from the apex (P<0.01). The R-Pilot file was significantly superior to PathFile in centering ability in mesiodistal direction at 1 mm from the apex (P<0.05). Canal transportation direction was towards the mesiolingual and distobuccal in R-Pilot and PathFile groups, respectively. **Conclusion:** Within the limitations of this study, the results showed that R-Pilot with reciprocal movement is a safe and easy to use instrument for creating a glide path.

Keywords: Canal Transportation; Cone-Beam Computed Tomography; Glide Path; PathFile; R-Pilot

Introduction

Root canal instrumentation is performed aiming to achieve a uniform taper from the access cavity towards the apex while preserving the original shape of the canal [1, 2]. Glide path refers to a straight path from the canal orifice to the physiologic root end. Several files can be used to create a glide path. The minimum file size is #10, which should be placed loose in the canal [3]. Not creating a glide path would result in ledge formation, canal transportation, canal obstruction and consequently under-filling of the root canal [4].

Apical transportation is defined as transportation of the physiologic apex of the canal to a new iatrogenic location on the external root surface [5, 6]. Also, creating a glide path prevents fracture of endodontic instruments. It serves as a safety feature in endodontic treatment and can be created manually or mechanically [7]. Stainless steel hand K-files can be used to create a glide path. The advantages of using hand K-files include excellent tactile sense and lower risk of file fracture. Using a small-size K-file in the root canal helps the operator to better perceive the curvature of the canal. It also helps in detection of calcified canals [8].

In 2008, a reciprocating handpiece attached to small size K-file was introduced for creating a glide path. Its main advantages include decreased time required for creating a glide path and less hand fatigue in narrow canals compared to the conventional manual techniques [8]. The R-Pilot characteristics include ISO 12.5 tip size and 4% taper. It is made of M-wire and has a reciprocating movement [9].

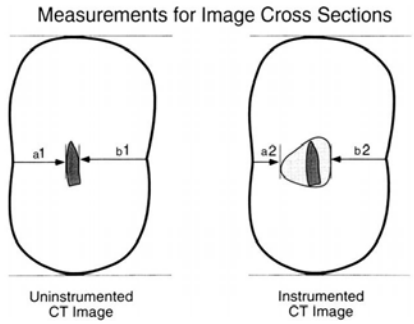

Figure 1. Centering ability was calculated using the following formula $(B_1-B_2)/(A_1-A_2)$ or $(A_1-A_2)/(B_1-B_2)$

PathFile rotary files are also used to create a glide path, which include three rotary instruments with a tip diameter of 0.13, 0.16 and 0.19 mm. They have a non-cutting tip to prevent ledge formation or zipping. This tip has a square-shaped cross-section with four cutting angles that increase the efficacy of PathFile for use in long, calcified canals. These files are made of nickel titanium alloy and have 2% taper, which increases their flexibility [4]. This *in vitro* study aimed to compare the change in root canal anatomy following creation of a glade path with two rotary systems in the mesiobuccal canal of maxillary first and second molars using cone-beam computed tomography (CBCT).

Materials and Methods

This *in vitro*, experimental study evaluated 60 maxillary first and second molars extracted for periodontal disease or prosthetic problems that met the following inclusion criteria. The inclusion criteria were mature apices [10], having a mesiobuccal root with two canals and separate apices or canals fused at the apical 5 mm [10, 11], 20-40° curvature (according to Schneider's method) [12], minimum length of 19 mm, from the tip of the mesiobuccal cusp to the apex [13], absence of canal calcification [14] and no history of previous treatment [14].

The teeth were mounted in silicon impression material (Speedex, Coltene/Whaledent, Altstatten, Switzerland) to have a standardized position for radiography. Mounted samples underwent parallel periapical radiography and a buccolingual radiograph was obtained to determine the position of canals. Coronal access cavity was prepared using a #4 round carbide bur (Dentsply Maillefer, Ballaigues, Switzerland). A #10 K-file was placed in the first and second mesiobuccal canals to assess the degree of canal curvature in mesiodistal direction according to the Schneider's technique [15]. The teeth were sectioned at the furcation area and the mesial half of the root and crown was separated. The working length was determined 1 mm short of the apical foramen using a #10 K-file. A periapical radiograpy was also obtained to ensure correct working length. Specimens were then randomly divided into two groups. The crowns were mounted in silicon putty impression material and scanned using a NewTom VGI CBCT system (QR SRL Co., Verona, Italy) with the following parameters: 9.5 mA, 110 kV, 5.4 sec scanning time, 0.125 mm voxel size and 0.125 mm axial thickness. The slices were obtained from the apical towards the coronal with 0.9 mm slice thickness, and sections at 1, 2 and 3 mm from the apex were evaluated. For easier introduction of files into the canals, coronal flaring was first performed with ProTaper rotary system (Dentsply Maillefer, Ballaigues, Switzerland) operating at 350 rpm with brushing movement using a 16:1 contra-angle handpiece [14].

In group 1, PF1 (0.13 mm) (Dentsply Maillefer, Ballaigues, Switzerland), PF2 (0.16 mm) and PF3 (0.19 mm) were used in an orderly fashion operating at 300 rpm and 5 N/cm torque with in-and-out movement to the working length, powered by an electric torque controlled motor (VDW Co, Munich, Germany). The canals were rinsed with 2 mL of distilled water using a 27-gauge needle after each use of rotary file [15].

In group 2, R-Pilot single file (VDW Co, Munich, Germany) was attached to the electric motor (Silver Reciproc Endomotor; VDW Co., Munich, Germany) and root canal was prepared with reciprocating movement of the file. Rinsing was performed as in group 1.

CBCT scans were taken again of the teeth using the same exposure settings to assess canal transportation and centering ratio. Canal transportation was determined using the formula below: $(B_1-B_2)-(A_1-A_2)$ where A_1 is the shortest distance from the mesial or lingual root margin to the mesial or lingual margin of the instrumented canal, B_1 is the shortest distance from the distal or buccal root margin to the distal or buccal margin of the instrumented canal, A_2 is the shortest distance from the mesial (lingual) root margin to the mesial (lingual) margin of the canal after instrumentation and B_2 is the shortest distance from the distal (buccal) root margin to the distal (buccal) margin of the canal after instrumentation.

Centering ability was calculated using the formula below (Figure 1) [14]: $(B_1-B_2)/(A_1-A_2)$ or $(A_1-A_2)/(B_1-B_2)$.

Statistical analysis

Data regarding the amount of transportation did not have a normal distribution. Thus, pairwise comparisons were carried out using the Mann Whitney-U test. The centering ratio data were analyzed using the *Chi*-square test and Fisher's exact test. All statistical analyses were carried out using Sigma Stat 4 software (Systat Software, Inc, San Jose, CA, USA).

Results

Canal transportation and centering ratio were evaluated for the two file types at three levels from the apex. Table 1 summarizes the results in this respect. As shown in Table 1, PathFile and R-Pilot were significantly different in terms of canal transportation in mesiodistal direction at 1 and 2 mm from the apex ($P<0.01$), but this difference was not significant at 3 mm from the apex. In terms of centering ratio in the mesiodistal direction, R-Pilot showed the highest centering ratio at 3 mm from the apex (46.7%) and the lowest centering ratio at 1 mm from the apex (10%). *Chi*-square test showed that this difference in centering ratio was statistically significant ($P<0.025$). For the PathFile, the difference in centering ratio was not significant at three levels from the apex ($P=0.5$).

Table 1 shows canal transportation and centering ability of PathFile and R-Pilot in buccolingual direction at different levels from the apex. As shown, canal transportation in buccolingual direction was significantly smaller following canal preparation with R-Pilot compared to PathFile at 1 mm from the apex. The difference in this respect was not significant at 2 and 3 mm from the apex ($P<0.7$). The Fisher's exact test showed that the higher centering ratio of PathFile at 1 mm from the apex and R-Pilot at 3 mm from the apex was significant compared to other levels ($P<0.05$). The difference in centering ability of the two files in buccolingual direction was not significant at any level from the apex ($P<0.4$).

Statistical analyses revealed that the R-Pilot system had the highest canal transportation towards the mesiolingual at 1, 2 and 3 mm from the apex. The PathFile system had the highest canal transportation towards the distobuccal at 1, 2 and 3 mm from the apex. In terms of centering ability, canal centering ratio was greater following the use of R-Pilot system at 1 and 2 mm from the apex (except for 2 mm level in buccolingual dimension) compared to the use of PathFile. This was reverse at 3 mm from the apex and the R-Pilot showed less centering ability than PathFile.

Discussion

Preserving the original anatomy of the root canal system is the cornerstone of a successful endodontic treatment. Many rotary systems have been introduced aiming to better preserve the original anatomy of root canals [10]. Preparation of curved canals is challenging and may be associated with procedural errors such as changing the degree of curvature or apical transportation. Creating a glide path is imperative to preserve canal anatomy and prevent endodontic instrument fracture [16, 17] .

The current study compared canal transportation and centering ratio following canal instrumentation with R-Pilot and PathFile using CBCT. Both systems showed no significant difference in terms of canal transportation and centering ability. Our findings demonstrated that R-Pilot caused less transportation at 1 and 2 mm from the apex and had higher centering ability at 1 mm from the apex.

According to Peters [18], canal transportation by 0.1 mm or less is clinically acceptable. In the current study, the mean apical transportation was less than this value.

Dhingra *et al.* [10], in 2016 evaluated and compared canal transportation and centering ability of V Glidepath2 and PathFile and showed that PathFile caused greater transportation and had lower centering ability. Their findings were in agreement with ours. They had a methodology similar to ours but assessed sections at 0 to 7 mm from the apex. They reported the magnitude of transportation and centering ratio following the use of PathFile at 0 to 7 mm from the apex. Also, they reported that transportation was towards the distal on all sections except for 0 mm from the apex, on which, transportation was slightly towards the mesial; and at 5 mm from the apex, which did not show any transportation. Their findings were comparable to our results [19].

Another study evaluated change in anatomy of curved canals of mandibular first molars following the use of V Glidepath2 and PathFile on CBCT scans. The results revealed that both files

Table 1. Mean canal transportation and centering ratio for PathFile and R-Pilot at different levels from the apex (MD=mesiodistal, BL=buccolingual, WL=working length)

BL transportation	MD transportation	Sample	MD centering ability		BL centering ability	
			+	-	+	-
PathFile1	0.95 (1.1)	1.36 (0.71)	26.7	73.3	23.3	76.7
PathFile2	1.2 (0.88)	1.4 (0.67)	36.7	63.3	0	100
PathFile3	0.8 (0.88)	0.9 (0.71)	36.7	63.3	6.64	93.36
R-Pilot 1	0.8 (0.55)	1.03 (0.7)	10	90	10	90
R-Pilot 2	0.8 (0.84)	1.3 (0.46)	20	80	10	90
R-Pilot 3	0.6 (0.62)	1.06 (0.46)	46.7	53.3	16.7	83.3

caused transportation towards the distal, which was in accord with our observations. However, centering ability of PathFile in their study was higher than that in our study [15]. This difference in the results may be due to the reciprocating movement or packing of debris.

The R-Pilot system has safe reciprocating movement in counterclockwise direction and then in clockwise direction for 10 cycles/sec. It gets involved with dentin and moves forward [20, 21]. This movement is highly safe and evidence shows increased longevity and decreased fatigue in use of this movement. The current results confirmed those of previous studies that used instruments with reciprocating movement [22-24]. Significant difference between R-Pilot and PathFile in this study may be due to the type of reciprocating movement and type of M-wire alloy in R-Pilot, which are associated with increased flexibility.

Use of CBCT in endodontic treatments has gained increasing popularity due to general access to software programs such as Photoshop [25]. This technique is more accurate than the conventional methods. This technique does not require destruction of samples and its results have high reproducibility. It provides numerous images of canals and comprehensive information about root canals before, during and after mechanical preparation [21, 26-29]. Also, it has small equipment and is affordable [30]. Despite the numerous advantages of CBCT, micro-CT remains the gold standard for the assessment of centering ratio of different files [13].

In the current study, mesiobuccal root canals of maxillary first and second molars were used because these canals often have significant curvatures [25, 31]. These roots are very thin and wide, which highly complicate their mechanical preparation [32]. On the other hand, the second mesiobuccal canal orifice is hardly detected because a dentinal ledge masks it [33]. Its orifice has a mesiobuccal slope over the pulp chamber floor. Canal path in the coronal section has one or two curvatures that further complicate the procedure [25, 34] .

Conclusion

Comparison of canal transportation and centering ratio following canal preparation with R-Pilot and PathFile systems on CBCT scans showed that the two systems were significantly different in this respect. R-Pilot caused less transportation at 1 and 2 mm from the apex and higher centering ability at 1 mm from the apex.

Acknowledgement

This research was carried out in cooperation with the Research Center of Shahed Dental School.

Conflict of Interest: 'None declared'.

References

1. West J. The endodontic Glidepath:" Secret to rotary safety". Dent today. 2010;29(9):86, 8, 90-3.
2. Coelho MS, Fontana CE, Kato AS, de Martin AS, da Silveira Bueno CE. Effects of glide path on the centering ability and preparation time of two reciprocating instruments. Iran Endod J. 2016;11(1):33.
3. West J. Manual versus mechanical endodontic glidepath. Dent today. 2011;30(1):136, 8, 40 passim.
4. Van der Vyver P. Creating a glide path for rotary NiTi instruments: Part Two. Int Den SA. 2011;13:14-25.
5. IB B. Ingle's Endodontics. 2008:1123.
6. Madani Z, Soleymani A, Bagheri T, Moudi E, Bijani A, Rakhshan V. Transportation and centering ability of neoniti and ProTaper instruments; A CBCT assessment. Iran Endod J. 2017;12(1):43.
7. Kubde R, Saxena A, Chandak M, Bhede R, Sundarkar P. Creating Endodontic Glidepath-A Review. Int J Dent Clin. 2012;4(2).
8. Van der Vyver P. Creating a glide path for rotary NiTi instruments: Part one. Int Den SA. 2011;13:6-10.
9. Ng FK, Messer LB. Mineral trioxide aggregate as a pulpotomy medicament: a narrative review. Eur Arch Paediatr Dent. 2008;9(1):4-11.
10. Dhingra A, Mangat P, Kawatra B. CBCT Evaluation Of Glidepath Preparation By Different Rotary Nickel Titanium Glide Path Instruments, V Glide Path 2 And Pathfiles In Root Canals Of Maxillary First Premolars-An Ex Vivo Study. IOSR.1(15):1-6.
11. Zuolo ML, Carvalho MC, De-Deus G. Negotiability of second mesiobuccal canals in maxillary molars using a reciprocating system. J Endod. 2015;41(11):1913-7.
12. Schneider SW. A comparison of canal preparations in straight and curved root canals. Oral Surg Oral Med Oral Pathol. 1971;32(2):271-5.
13. Moghadam KN, Shahab S, Rostami G. Canal transportation and centering ability of twisted file and reciproc: a cone-beam computed tomography assessment. Iran Endod J. 2014;9(3):174.
14. Gergi R, Rjeily JA, Sader J, Naaman A. Comparison of canal transportation and centering ability of twisted files, Pathfile-ProTaper system, and stainless steel hand K-files by using computed tomography. J Endod. 2010;36(5):904-7.
15. Dhingra A, Manchanda N. Modifications in Canal Anatomy of Curved Canals of Mandibular First Molars by two Glide Path Instruments using CBCT. J Clin Diagn Res. 2014;8(11):ZC13.
16. Martin N, Jedynakiewicz NM, Fisher AC. Hygroscopic expansion and solubility of composite restoratives. Dent Mater. 2003;19(2):77-86.

17. Berutti E, Cantatore G, Castellucci A, Chiandussi G, Pera F, Migliaretti G, Pasqualini D. Use of nickel-titanium rotary PathFile to create the glide path: comparison with manual preflaring in simulated root canals. J Endod. 2009;35(3):408-12.
18. Peters OA. Current challenges and concepts in the preparation of root canal systems: a review. J Endod. 2004;30(8):559-67.
19. Dhingra A. Canal anatomy modifications by using path files, glide path instruments analysed by Cone Beam Computed Tomography. IOSR.1(10):1-6.
20. El Batouty KM, Elmallah WE. Comparison of canal transportation and changes in canal curvature of two nickel-titanium rotary instruments. J Endod. 2011;37(9):1290-2.
21. Gambill JM, Alder M, Carlos E. Comparison of nickel-titanium and stainless steel hand-file instrumentation using computed tomography. J Endod. 1996;22(7):369-75.
22. Paqué F, Zehnder M, De-Deus G. Microtomography-based comparison of reciprocating single-file F2 ProTaper technique versus rotary full sequence. J Endod. 2011;37(10):1394-7.
23. Yared G. Canal preparation using only one Ni-Ti rotary instrument: preliminary observations. Int Endod J. 2008;41(4):339-44.
24. You S-Y, Kim H-C, Bae K-S, Baek S-H, Kum K-Y, Lee W. Shaping ability of reciprocating motion in curved root canals: a comparative study with micro–computed tomography. J Endod. 2011;37(9):1296-300.
25. Hartmann MSM, Barletta FB, Fontanella VRC, Vanni JR. Canal transportation after root canal instrumentation: a comparative study with computed tomography. J Endod. 2007;33(8):962-5.
26. Howerton Jr WB, Mora MA. Advancements in digital imaging: what is new and on the horizon? J Am Dent Assoc. 2008;139:S20-S4.
27. Versiani MA, Pascon EÁ, de Sousa CJA, Borges MAG, Sousa-Neto MD. Influence of shaft design on the shaping ability of 3 nickel-titanium rotary systems by means of spiral computerized tomography. Oral Surg Oral Med Oral Pathol Oral Radiol Endod. 2008;105(6):807-13.
28. Delgoshayi N, Abbasi M, Bakhtiar H, Sakhdari S, Ghannad S, Ellini MR. Canal Transportation and Centering Ability of ProTaper and SafeSider in Preparation of Curved Root Canals: A CBCT Evaluation. Iran Endod J. 2018;13(2):240.
29. Moazzami F, Khojastepour L, Nabavizadeh M, Habashi MS. Cone-beam computed tomography assessment of root canal transportation by neoniti and reciproc single-file systems. Iran Endod J. 2016;11(2):96.
30. Scarfe WC FA, Sukovic P. Clinical applications of cone-beam computed tomography in dental practice. J Can Dent Assoc. 2006;72(1):75-80.
31. Madani Zs, Goudarzipor D, Haddadi A, Saeidi A, Bijani A. A CBCT Assessment of apical transportation in root canals prepared with hand k-flexofile and K3 rotary instruments. Iran Endod J. 2015;10(1):44.
32. Rezaeian M, Tonekaboni MR, Iranmanesh F. Evaluating the Root Canal Morphology of Permanent Maxillary First Molars in Iranian Population. Iran Endod J. 2018;13(1):78.
33. Khademi A, Naser AZ, Bahreinian Z, Mehdizadeh M, Najarian M, Khazaei S. Root morphology and canal configuration of first and second maxillary molars in a selected Iranian population: A cone-beam computed tomography evaluation. Iran Endod J. 2017;12(3):288.
34. Rhodes J, Ford TP, Lynch J, Liepins P, Curtis R. Micro-computed tomography: a new tool for experimental endodontology. Int Endod J. 1999;32(3):165-70.

Please cite this paper as: Nazari Moghadam K, Teimoori S, Labbaf H, Kazemi A, Kavosi A, Mahdavi F. Canal Transportation and Centering after Using PathFile and R-Pilot in Mesiobuccal Canals of Maxillary Molars Using Cone-beam Computed Tomography. Iran Endod J. 2019;14(1): 35-9. *Doi*: *10.22037/iej.v14i1.21601*.