

See discussions, stats, and author profiles for this publication at: <https://www.researchgate.net/publication/281035250>

Immediate Loading of Microtextured Single-Tooth Implants

Article · March 2015

DOI: 10.17795/ajdr-21477

CITATIONS

0

READS

48

5 authors, including:



Hassan Semyari

Shahed University

20 PUBLICATIONS 74 CITATIONS

[SEE PROFILE](#)



Sayed Shojaedin Shayegh

Shahed University

17 PUBLICATIONS 53 CITATIONS

[SEE PROFILE](#)



Farshid Bastami

Shahid Beheshti University of Medical Sciences

31 PUBLICATIONS 209 CITATIONS

[SEE PROFILE](#)

Some of the authors of this publication are also working on these related projects:



Bone tissue engineering and regenerative medicine [View project](#)



Induced pluripotent stem cells as a new gateway for bone tissue engineering: A systematic review [View project](#)

Immediate Loading of Microtextured Single-Tooth Implants

Hassan Semyari¹; Seyed Shojaoddin Shayegh²; Toktam Jalayer³; Mohammad Bagher Alkhafaf⁴; Farshid Bastami^{4,*}

¹Department of Periodontology, Dental School of Shahed University, Tehran, IR Iran

²Department of Prosthodontology, Dental School of Shahed University, Tehran, IR Iran

³Department of Radiology, Dental School of Shahed University, Tehran, IR Iran

⁴Dental School of Shahed University, Tehran, IR Iran

*Corresponding author: Farshid Bastami, Dental School of Shahed University, Italy St, Vesal Ave, Keshavarz Blv, Tehran, IR Iran. Tel: +98-2188959210, Fax: +98-2188954915, E-mail: farshid_bst@yahoo.com

Received: July 16, 2014; Revised: November 22, 2014; Accepted: November 30, 2014

Background: The Immediate loading (IL) protocol has gained increased popularity among surgeons in the last decade.

Objectives: This study aimed to evaluate the clinical performance of microtextured single-tooth implants using IL protocol six months after loading.

Patients and Methods: In this case series, SwissPlus implants (Zimmer Dental Inc, Carlsbad CA, USA) which was straight, self-tapping, 12 mm length and 4.1 mm diameter, were inserted into both jaws and single edentulous sites with clinically and radiologically healed bone by an experienced surgeon. In the test group (with IL protocol), one week after the surgery, the provisional crowns and abutments were loaded, and definitive restorations were delivered three months postoperatively. The factors including pain, mobility, probing depth (PD), bleeding on probing (BOP) and marginal bone loss (MBL) were investigated six months after the IL. The Mc Nemar and Wilcoxon tests were used for nominal variables and the paired ttest was also used for quantitative variables.

Results: Twenty-five implants were placed in 23 patients at Dental School of Shahed University, Tehran, Iran. The test group included 15 patients (16 implants) treated with immediately loaded single-tooth implants. The survival rate was 100% in both groups. In test, a significant reduction was measured in PD and pain; moreover, no statistically significant difference was noted between follow-ups with regard to mobility and BOP. The mean PD values six months for test and nine months for control after installation were 2.548 mm and 2.694 mm, respectively. Marginal bone loss was significantly decreased in the test group between the follow-ups.

Conclusions: Consequently, this study shows promising results for IL of single implants, and it can be considerable that treatment with microtextured surface implants is a predictable and appropriate method of treatment.

Keywords: Immediate Dental Implant Loading; Dental Implants, Single-Tooth; Microtextured Surface; SwissPlus Implant

1. Background

Losing a tooth may cause cosmetic or functional impairment (1). There are different treatments for single-tooth replacement, which possible advantages and disadvantages should be considered before deciding on treatment. Benefits of dental implants have prompted other patients to accept the implant insertion (2, 3). In fact, single implants supporting single crowns demonstrated high long-term survival rates (4). In addition to implant survival rates, with regarding to determine the clinical success of treatment, stability of both marginal bone and soft tissues around dental implants are important (5). The immediate loading (IL) protocol is an implant-based temporal or final restoration in which occlusal contact occurs within two weeks of the implant insertion (6). Since IL protocol on osseointegrated dental implants shortens the duration of treatment (7) and may have esthetic importance for patients especially in the appearance zone (8), nowadays IL protocols not only

have gained popularity near surgeons but also have shown patient satisfaction outcomes in last studies (9-11). The one-step procedure also reduces the cost and time of the treatment (12).

Surface characteristics are one of the variables that directly affect the survival rate of dental implants (13, 14). In a histometric study, to compare the machined and microtextured surface implants in low-density maxilla bone in human, it was found that bone formation was significantly greater in the microtextured surfaces (15).

2. Objectives

The present prospective study aimed to evaluate the clinical and radiological aspects of IL protocol on implants with moderately rough and microtextured surfaces created by blasting with soluble hydroxyapatite as single-tooth implants in healed socket.

3. Patients and Methods

3.1. Study Population

In this case series study, 23 qualified patients referred to the Dental School of Shahed University were recruited during two years. All patients were aware of the study design and the potential risks and complications of the treatment, and an informed consent was obtained from the participants. Moreover, the study protocol conformed to the ethical guidelines of the 1975 Declaration of Helsinki. The patients were divided into two groups of test with 15 patients (6 men and 9 women, age: 43.63 ± 9.10 years, range from 30 to 60 years) and control with 8 patients (3 men and 5 women, age: 45.11 ± 5.79 years, range from 36 to 55).

Inclusion criteria included loss of a tooth, no periodontal disease, and proper bone volume and maxillo-mandibular relation. Exclusion criteria included: a) extraoral: patients at growing age, any systemic disease, consumption of anticancer drugs and corticosteroids, smoking (more than 20 cigarettes per day); b) intraoral: parafunctional habits such bruxism, cross-bite, deep-bite, clenching, periodontal disease, poor oral hygiene, poor bone quality and quantity.

3.2. Implant System Overview

The SwissPlus implants (Zimmer Dental Inc, Carlsbad CA, USA) used for all patients were straight and self-tapping type with 12 mm length and 4.1 mm diameter. They were flat-based and their indentation depth was 0.3 mm; the distance between indentation and thread pitch was 0.9 mm. Indentation depth started from 0.3 mm at the apex of the implant and increased to 0.6 mm at the highest indentation.

The implants used in this study have a common, prosthetic platform 4.8 mm in diameter with an internal, 8-degree bevel-and-octagon connection, and they were manufactured from grade 4, commercially-pure titanium (CP Ti) (99%) that is work-hardened to provide a tensile strength of approximately 895 MPa.

3.3. Surgery Procedures

Patients received amoxicillin, 2 g one hour before surgery as prophylactic antibiotic and 500 mg three times a day for one week after surgery (16). The initial oral examination included the evaluation of quality and quantity of the bone, jaw relations, and necessary radiographs (panoramic and computed tomography scan), as well as systemic status. Patients were operated by a surgeon in the implant department of Dental School of Shahed University under sterile conditions and following washing the mouth with chlorhexidine 0.2% for 30 seconds.

After the elevation of rectangular flap, implant insertion was performed in the first step by a pilot drill of 2.3 mm diameter, in the second step by an intermediate

drill of 2.8 mm diameter, and in the third step by a final drill of 3.5 mm diameter. In fact, surgical protocol and implant insertion was in accordance with the literature (17). The insertion site was thoroughly washed during each step. A guide pin (depth guide) was also used to determine the depth of socket between the steps. The implant was then inserted using ratchet, and a force of 30 N was applied to the implant with a torque control ratchet to confirm its primary stability in the bone. The mount screw was loosened by a hextool (diameter of 1.25) and removed by a frictional hextool and a cover screw was mounted. Then a crescent was cut out to match the tissue around the implant and the flap edges were interruptedly sutured using a braided silk 3-0 and a reverse-cutting needle (Figure 1).

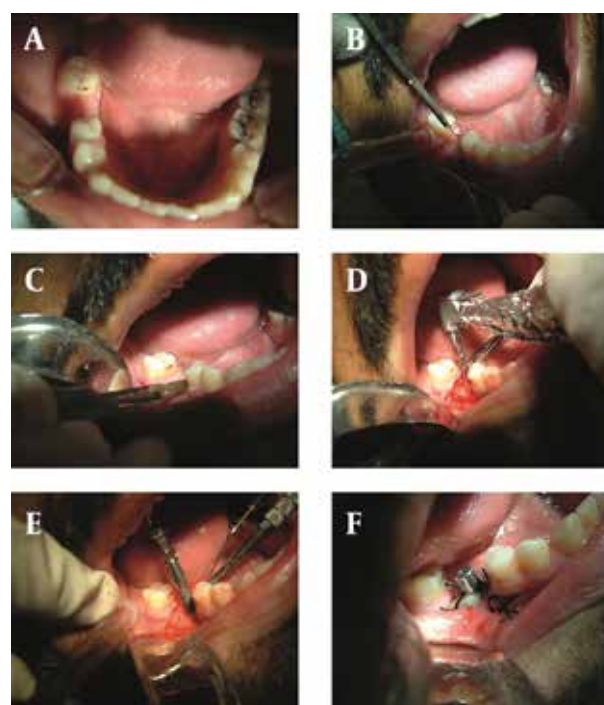


Figure 1. Surgery Procedures and Insertion of a Single-Tooth Implant

Finally, ibuprofen 200 mg every eight hours and chlorhexidine 0.2% mouthwash twice a day for two weeks were administered.

3.4. Prosthesis Procedures

In the test group, the abutment was connected to the fixture and was imprinted with putty in the prosthesis department, the day after surgery. The cover screw was then back to the fixture and jaw relation of the patient was obtained from the centric occlusion position. The abutment was tightly screwed to the fixture seven to ten days after surgery and removing the stitches, and the acrylic temporary crown was mounted on the abutment according to the laboratory instructions. All existing premature contacts on the temporary crown in centric and

eccentric positions and all possible premature contacts within the patient's mouth were removed and a gentle contact was created between the temporary prosthesis and the opposite teeth. In the control group, the loading was applied three months after implantation.

3.5. Clinical and Radiological Evaluations

Clinical variables measured by an examiner during the loading day, and one month, three months, and six months after the loading included probing depth (PD; longitudinal distance between the gingival margin to the pocket base), mobility (measured with a pressure equivalent to 500 g on temporary crown), pain (measured with a pressure equivalent to 500 g on temporary crown), and bleeding on probing (BOP; bleeding more than 20 seconds after probing around the implant), and marginal bone loss radiographic variables (MBL; distance between the platform and bone crest at the mesial and distal sides). Mobility and PD were also measured in the surgery and impression days.

Intraoral radiovisography (RVG) was performed in radiology department during follow-up using Prostyle In-tra (Planmeca) intraoral tube with an average cone (KVP60, 0.12 or 0.16 seconds) through parallel technique by the RVG film holder. A putty impression was prepared and registered for each patient and used for the next radiographies with same radiation conditions.

Upon the completion of the work, all radiographs were evaluated using the Trophyviewer software. Measurements were performed on radiographs by Photoshop, regarding the distance between the two consecutive implant threads (0.9 mm). The SPSS, McNemar and Wilcoxon tests were used for nominal variables and paired t-test for quantitative variables.

4. Results

Of total 25 implants inserted as single tooth, 16 implants belonged to the test group (11 in mandible and five in maxilla) and nine implants (Five in mandible and four in maxilla) to the control group which their location showed in Table 1. There was no significant difference between ages of both groups ($P = 0.664$). No failure was observed and the success rate was 100%.

The mean PD was 2.548 mm and 2.694 mm in the test and control groups, respectively. No significant difference was observed in PD of mesiobuccal, distobuccal, and buccal areas of the implants in both groups during follow-up days ($P > 0.05$) (Figure 2), while PD in the palatal (lingual) area had a significant difference in the test group ($P = 0.026$).

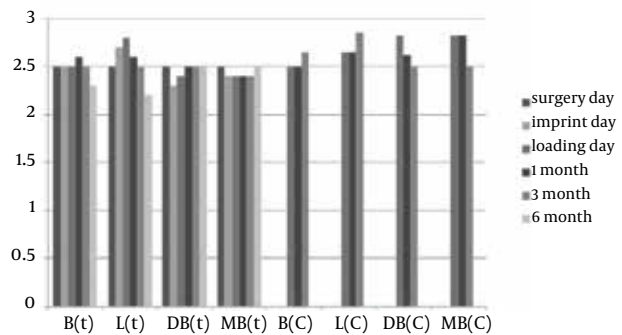
No significant difference was found in BOP of the surgery day and follow-up days in both groups. No mobility was observed in the test and control groups in all examinations. Pain was significantly reduced in the test group at the surgery day compared with follow-up days ($P = 0.0431$).

RVG analysis showed that unlike the control group, comparison of MBL between follow-up days was significantly toward increase in bone formation in the test group (Figure 3 and Table 2).

Table 1. Location of Implant Placement in Both Test and Control Groups

	Test	Control	Total
Mandible			
First molar	9	4	13
Second molar	2	1	3
Maxilla			
Canine	1	0	1
First premolar	2	2	4
Second premolar	1	1	2
First molar	1	1	2
Total	16	9	25

Figure 2. The Mean probing depth in Both Test and Control Groups During Follow-up Appointments



B (t), Buccal side of the test group; L (t), Lingual side of the test group; DB (t), Distobuccal side of the test group; MB (t), Mesiobuccal side of the test group; B (C), Buccal side of the control group; L (C), Lingual side of the control group; DB (C), Distobuccal side of the control group; MB (C), Mesiobuccal side of the control group

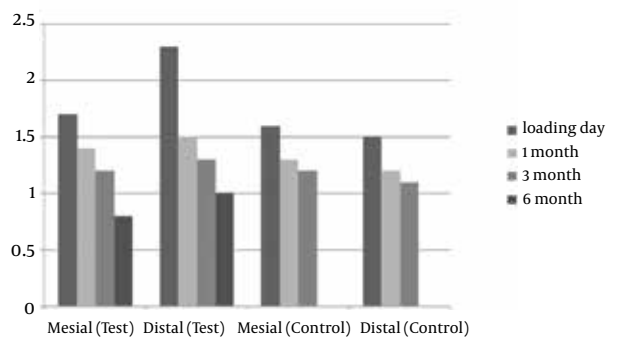


Figure 3. The Mean Distance Between Implant Plat Form and Crestal Bone in Both Test and Control Groups During Follow-up Appointments

Table 2. Comparison of The Mean Distance Between Implant Plat Form and Crestal Bone Between Follow-up Days Toward Increase in Bone Formation in the Test Group According to Paired t-test.

	Mesial (P value)	Distal (P value)
Loading day - 1 month	0.009	0.004
Loading day- 3 months	0.017	0.008
Loading day- 6 months	0.003	0.054
1 month - 3 months	0.025	0.003
1 month- 6 months	0.003	0.001
3 months - 6 months	0.019	0.059

5. Discussion

In the present study, performance of the IL protocol for single implants with moderately rough and micro-textured surface had a survival rate of 100%, which is acceptable and satisfactory. However, it should be noted that 10 implants in the test group were in the lower molar region (18). There are reports of survival rate of 97% for single-tooth implants with different systems (1, 19, 20) and of 97.5% for IL protocol for single-tooth implants (21). Furthermore, according to the recent 5-year prospective evaluation, the survival rate of immediate provisionalization of single tooth implants placed in anterior maxillary healed ridge was 98.3% (22). In fact, Benic et al. revealed no significant differences between survival rate of IL and conventional loading protocols (23). In addition, according to a recent review, stronger bone apposition was observed with rougher implant surfaces than with polished or turned surfaces (24); in fact, regarding the second consensus conference of the European Association of Osseointegration, both moderately rough and rough surfaces had more favorable bone reactions compared to both smooth and minimally rough surfaces. Furthermore, moderately rough surfaces were noticed to promote the highest bone-to-implant contact (BIC) values (25).

Periodontal status improvement in the lingual (palatal) side can be related to the observation of better health and self cleansing. The mean PD was 2.548 mm and 2.694 mm in the test and control groups, respectively, which showed more improvement of periodontium in the test group. In a previous study of this system as a single tooth implant and conventional loading, the PD was reported as 2.8 (1). Also, it is consistent with previous literature (18).

Lack of loosening in the test group may arise from the soft contact between the crown and opposite teeth created after insertion of the temporary crown. However, lack of mobility in the control group seems normal, since the permanent crown was inserted three months after the surgery, when the bone connection stage has been completed (12).

Pain reduction among the test patients had a signifi-

cant difference between the surgery and impression days and one month after the loading, which seems normal regarding the wound healing after surgery. However, no significant difference was observed in terms of pain, after loading at different time intervals, indicating a proper pressure on the temporary crown.

A four-year study on 1301 implants showed that the temporary crown type also affects the success rate significantly, such that the highest failure rate was seen in implants covered with plastic crowns. Therefore in this study, we used acrylic crowns in the test group (26). Another important point in previous studies was the starting day of loading in the IL protocol. In almost all cases, the implants with temporary coats during surgery failed, while in this study, the temporary crown placement on the implant was at the same time of stitches removal after surgery (27). At this time, the granulation tissue was formed around the implant and thus applying appropriate occlusal forces on crown surface can be effective in accelerating the transformation of granulation tissue and formation of bone. The positive slope of the curve represents the bone formation and proper distribution of occlusal forces on the implant surface.

Comparison of MBL in the test group between the loading day and one month, three months, and six months after loading showed no significant difference. The curve slope in this group showed bone formation and lack of per-implant resorption. The mean MBL with different loadings was reported as 0.2 mm which corresponds with our results (28, 29). To illustrate, the recent meta-analysis and systematic re-view demonstrated no significant differences between IL and conventional protocols with regards to MBL (23, 30).

The question is why a statistically significant difference was not found when studying MBL at one month, two months, and three months after loading in the control group using these implants. In other words, why bone was not formed in the cervical area of the control implants? Perhaps the reason is the loading time on the implant. Previous research of Piattelli (1997) was also noted this problem (31). These studies suggest that if the amount and time of loading is suitable and the implant surface is ready for osseointegration, bone formation will be possible; this is consistent with the results of the present study. However, an important difference of this study with other similar studies is not using the bone substitute materials, showing that the bone was formed merely on implant surface covered by HA (MTX process) and applying a suitable pressure. Further research is required to investigate the causes and circumstances of bone formation in longer periods.

According to the results, it seems that the possibility of osseointegration is very high when an appropriate loading was applied on the implant through IL protocol one week after surgery. In addition, the results of treatment with microtextured surface implants were predictable and appropriate.

Acknowledgements

We really want to thank the staff of Implantology Department of Dental School of Shahed University.

Authors' Contributions

1- Study concept and design: Semyari, Shayegh 2- Acquisition of data: Semyari, Shayegh, Jalayer, Alkhafaf, Bastami 3- Analysis and interpretation of data: Jalayer, Alkhafaf, Bastami 4- Drafting of the manuscript: Bastami 5- Critical revision of the manuscript for important intellectual content: Semyari, Shayegh, Jalayer 6- Statistical analysis: Jalayer, Bastami 7- Administrative, technical, and material support: Semyari, Shayegh, Jalayer 8- Study supervision: Semyari, Shayegh, Jalayer, Bastami

References

- Demiralp B, Muhtarogullari M, Hakki SS. Clinical and Radiographical Analysis of Single-Tooth Replacement with Swissplus Implant System. *Faculty of Dentistry, Hacettepe Journal*. 2006(1):57-62.
- Kosinski TF, Skowronski R. Immediate implant loading: a case report. *J Oral Implantol*. 2002;28(2):87-91.
- Semyari H, Heravi M, Shayegh S, Azar R, Bastami F. Comparison of Quality of Life Between Iranians Using Two Implant-Retained Overdenture Prosthesis and Conventional Complete Denture. *Avicenna journal of dental research*. 2013;5(2).
- Jung RE, Zembic A, Pjetursson BE, Zwahlen M, Thoma DS. Systematic review of the survival rate and the incidence of biological, technical, and aesthetic complications of single crowns on implants reported in longitudinal studies with a mean follow-up of 5 years. *Clin Oral Implants Res*. 2012;23 Suppl 6:2-21.
- den Hartog L, Raghoebar GM, Stellingsma K, Vissink A, Meijer HJ. Immediate non-occlusal loading of single implants in the aesthetic zone: a randomized clinical trial. *J Clin Periodontol*. 2011;38(2):186-94.
- Misch CE, Wang HL, Misch CM, Sharawy M, Lemons J, Judy KW. Rationale for the application of immediate load in implant dentistry: Part I. *Implant Dent*. 2004;13(3):207-17.
- Piattelli A, Ruggeri A, Franchi M, Romasco N, Trisi P. An histologic and histomorphometric study of bone reactions to unloaded and loaded non-submerged single implants in monkeys: a pilot study. *J Oral Implantol*. 1993;19(4):314-20.
- Rocci A, Martignoni M, Gottlow J. Immediate loading of Branemark System TiUnite and machined-surface implants in the posterior mandible: a randomized open-ended clinical trial. *Clin Implant Dent Relat Res*. 2003;5 Suppl 1:57-63.
- Kan JY, Rungcharassaeng K, Lozada J. Immediate placement and provisionalization of maxillary anterior single implants: 1-year prospective study. *Int J Oral Maxillofac Implants*. 2003;18(1):31-9.
- Lindeboom JA, Frenken JW, Dubois L, Frank M, Abbink I, Kroon FH. Immediate loading versus immediate provisionalization of maxillary single-tooth replacements: a prospective randomized study with BioComp implants. *J Oral Maxillofac Surg*. 2006;64(6):936-42.
- Hall JA, Payne AG, Purton DG, Torr B, Duncan WJ, De Silva RK. Immediately restored, single-tapered implants in the anterior maxilla: prosthodontic and aesthetic outcomes after 1 year. *Clin Implant Dent Relat Res*. 2007;9(1):34-45.
- Lata J, Parmar M. Placement of single tooth implant in healed socket with immediate temporization: Clinical study. *Contemp Clin Dent*. 2012;3(4):412-5.
- Rosenlicht JL. SwissPlus Implant System, Part 1: Surgical aspects and intersystem comparisons. *Implant Dent*. 2002;11(2):144-53.
- Nkenke E, Fenner M. Indications for immediate loading of implants and implant success. *Clin Oral Implants Res*. 2006;17 Suppl 2:19-34.
- Trisi P, Rao W, Rebaudi A. A histometric comparison of smooth and rough titanium implants in human low-density jawbone. *Int J Oral Maxillofac Implants*. 1999;14(5):689-98.
- Anand U, Mehta DS. Evaluation of immediately loaded dental implants bioactivated with platelet-rich plasma placed in the mandibular posterior region: A clinico-radiographic study. *J Indian Soc Periodontol*. 2012;16(1):89-95.
- Gunaseelan R, Rajan M. Overview of the SwissPlus Implant System. *J Oral Implantol*. 2005;31(3):121-8.
- Meloni SM, De Riu G, Pisano M, De Riu N, Tullio A. Immediate versus delayed loading of single mandibular molars. One-year results from a randomised controlled trial. *Eur J Oral Implantol*. 2012;5(4):345-53.
- Torabinejad M, Anderson P, Bader J, Brown LJ, Chen LH, Goodacre CJ, et al. Outcomes of root canal treatment and restoration, implant-supported single crowns, fixed partial dentures, and extraction without replacement: a systematic review. *J Prosthet Dent*. 2007;98(4):285-311.
- Quirynen M, Van Assche N, Botticelli D, Berglundh T. How does the timing of implant placement to extraction affect outcome? *Int J Oral Maxillofac Implants*. 2007;22 Suppl:203-23.
- Knoernschild KL. Early survival of single-tooth implants in the esthetic zone may be predictable despite timing of implant placement or loading. *J Evid Based Dent Pract*. 2010;10(1):52-5.
- Cooper LF, Reside GJ, Raes F, Garriga JS, Tarrida LG, Wiltfang J, et al. Immediate Provisionalization of Dental Implants Placed in Healed Alveolar Ridges and Extraction Sockets: A 5-year Prospective Evaluation. *Int J Oral Maxillofac Implants*. 2014;29(3):709-17.
- Benic GI, Mir-Mari J, Hammerle CH. Loading protocols for single-implant crowns: a systematic review and meta-analysis. *Int J Oral Maxillofac Implants*. 2014;29 Suppl:222-38.
- Wennerberg A, Albrektsson T. Effects of titanium surface topography on bone integration: a systematic review. *Clin Oral Implants Res*. 2009;20 Suppl 4:172-84.
- Lang NP, Jepsen S, Working G. Implant surfaces and design (Working Group 4). *Clin Oral Implants Res*. 2009;20 Suppl 4:228-31.
- Hruska A, Borelli P, Bordanaro AC, Marzaduri E, Hruska KL. Immediate loading implants: a clinical report of 1301 implants. *J Oral Implantol*. 2002;28(4):200-9.
- Rocci A, Martignoni M, Gottlow J. Immediate loading in the maxilla using flapless surgery, implants placed in predetermined positions, and prefabricated provisional restorations: a retrospective 3-year clinical study. *Clin Implant Dent Relat Res*. 2003;5 Suppl 1:29-36.
- Esposito M, Grusovin MG, Maghahre H, Worthington HV. Interventions for replacing missing teeth: different times for loading dental implants. *Cochrane Database Syst Rev*. 2013;3:CD003878.
- Berberi AN, Sabbagh JM, Aboushelib MN, Noujeim ZF, Salameh ZA. A 5-year comparison of marginal bone level following immediate loading of single-tooth implants placed in healed alveolar ridges and extraction sockets in the maxilla. *Front Physiol*. 2014;5:29.
- Suarez F, Chan HL, Monje A, Galindo-Moreno P, Wang HL. Effect of the timing of restoration on implant marginal bone loss: a systematic review. *J Periodontol*. 2013;84(2):159-69.
- Piattelli A, Paolantonio M, Corigliano M, Scarano A. Immediate loading of titanium plasma-sprayed screw-shaped implants in man: a clinical and histological report of two cases. *J Periodontol*. 1997;68(6):591-7.