Interlibrary Loans, Colorado State University

REJ-10123593

LDL

informahealth x -- http://rapidill.org/redir.ashx?id=Mjc4MDI1NjI=
Rapid# -4120249 kw

University of Nebraska

ATTN:		SUBMITTED:	2011-02-10 01:04:35
PHONE:	(402) 472-2522	PRINTED:	2011-02-10 08:57:04
FAX:	402-472-5181	REQUEST NO.:	REJ-10123593
E-MAIL:		SENT VIA:	Rapid ILL

REJ Regular Journal

TITLE:	Immunopharmacology and immunotoxicology [electronic resource].
VOLUME/ISSUE/PAGES:	33(1) 28-33
DATE:	2011
AUTHOR OF ARTICLE:	Sedaghat R, Ghazanfari T.
TITLE OF ARTICLE:	The immunomodulatory effects of Pleurotus florida on cell-mediated immunity and secondary lymphoid tissues in Balb/c mic
ISSN:	0892-3973
CALL NUMBER:	http://rapidill.org/redir.ashx?id=Mjc4MDI1NjI=
DELIVERY:	Ariel: 129.82.28.195
REPLY:	Mail:

This document contains 1 page. This is NOT an invoice.

Immunopharmacology and Immunotoxicology, 2011; 33(1): 28–33

informa
healthcare

Immunopharmacology and Immunotoxicology Downloaded from informahealthcare.com by Colorado State University on 02/10/11
For personal use only.

RESEARCH ARTICLE

The immunomodulatory effects of *Pleurotus florida* on cell-mediated immunity and secondary lymphoid tissues in Balb/c mice

Reza Sedaghat[1,2], and Tooba Ghazanfari[1,3]

[1]*Immunoregulation Research Center, Shahed University, Tehran, I.R. Iran,* [2]*Department of Anatomy and Pathology, Shahed University, Tehran, I.R. Iran, and* [3]*Department of Immunology, Shahed University, Tehran, I.R. Iran*

Abstract

This study aimed to evaluate the immunomodulatory effects of *Pleurotus florida* on cell-mediated immunity in Balb/c mice. Aqueous extract of *P. florida* was isolated, lyophilized, and stored in refrigerator until application. Forty female Balb/c mice were randomly divided into seven test and one control groups. Four groups received 10, 20, 50, or 100 mg/kg/day of *P. florida* extract intraperitoneally, whereas three others received 200, 500, or 1000 mg/kg/day by oral administration. Moreover, the control group received the same volume of normal saline intraperitoneally. The treatments were continued once a day for 2 weeks. Then, delayed type hypersensitivity (DTH), viability of splenic cells, and histology of secondary lymphoid tissues were examined. The results showed that DTH responses were not affected by various doses of the *P. florida* in different routes. However, a significant decrease in splenic cells viability was observed in groups treated with intraperitoneal injection of 10, 20, and 50 mg/kg of the *P. florida* extract. In contrast, oral administration of 1000 mg/kg of the extract caused a significant increase in viability of splenic cells. Although atrophic changes in spleen and lymph nodes were observed in some peritoneal injected groups, some doses of oral administration were lead to hyperplastic changes. The results of this study indicated that the effects of *P. florida* on cellular responses depends on dose and route of administration.

Keywords: *Pleurotus florida; immunomodulatory; cell-mediated immunity; spleen; lymph nodes; histology*

Introduction

Immunomodulators are the valuable components that affect immune responses. These components have been considered to be useful in controlling and treatment of diseases. Medicinal mushrooms are valuable source of active elements and are beneficial for health (1,2). In ancient times, they have been used in folk medicine for treatment of a variety of human diseases (3). Basidiomycete mushrooms possess immune modulating, antihypercholesterolemic, antiviral, antibacterial, and antiparasitic effects (4,5). *Pleurotus* belongs to species of the basidiomycete class of fungi (2) and has been regarded as an edible mushroom for many years (6,7). *P. florida,* a mushroom which belongs to the genus *Pleurotus*, possess antioxidant, immunostimulator, antitumor and anti-inflammatory activities (5,6,8).

In a previous study, we investigated the effect of *P. florida* on innate immune system. We considered the effects of *P. florida* on nitric oxide (NO) production and cell viability of macrophages *in vitro* and *in vivo*. *In vivo* findings indicated that oral administration of *P. florida* at the doses of 200, 500, and 1000 mg/kg/day significantly increased cell viability of macrophages. Furthermore, NO production was significantly increased following higher doses of *P. florida*, i.e., 500 and 1000 mg/kg/day. On the other hand, intraperitoneal (i.p.) injection of *P. florida* at the doses of 10, 20, 50, 100 mg/kg/day significantly decreased NO production by macrophages and was not effective on cell viability of macrophages (4). *In vitro* works showed that almost all applied doses of *P. florida*

Address for Correspondence: Tooba Ghazanfari, Associate Professor, Department of Immunology, Shahed University, Tehran,. 14155-7435, Iran. E-mail: tghazanfari@yahoo.com; ghazanfari@shahed.ac.ir

(Received 05 January 2010; revised 05 February 2010; accepted 10 February 2010)

ISSN 0892-3973 print/ISSN 1532-2513 online © 2011 Informa Healthcare USA, Inc.
DOI: 10.3109/08923971003691916

RIGHTSLINK

Immunopharmacology and Immunotoxicology Downloaded from informahealthcare.com by Colorado State University on 02/10/11
For personal use only.

extract significantly increased cell viability and was not effective on NO production in comparison to the control group (6).

Some studies have shown that *P. florida* mushroom possess significant antioxidant, antitumor properties and antiplatelet aggregation activity (8,9). Rout et al. (10) reported that a glucan isolated from the aqueous extract of *P. florida* stimulates the phagocytic activity of macrophages and has anti-inflammatory and immunomodulatory functions (10). Because the effect of *P. florida* on cell-mediated immunity is not reported up to now, this study was conducted to examine the effect(s) of various concentrations of *P. florida* extract administrating through different routes on delayed type hypersensitivity (DTH), viability of spleen cells, and histology of secondary lymphoid tissues in Balb/c mice.

Materials and methods

Animals

Eight- to ten-week-old inbred female Balb/c mice were purchased from Razi Institute (Tehran, Iran) and maintained in animal laboratory at Shahed University, Tehran, Iran. Animals were maintained in the standard environmental conditions. Forty mice were allocated in eight groups, including a control and seven test groups (five animals/group).

Preparation of the extract

Fresh mushroom sample was purchased from Booshehr, Iran. We prepared the *florida* extract by mixing 42.5 g of *florida* with 155 cc deionized and distilled water. The solution was centrifuged at 14,000*g* for 20 min. Supernatant was collected, lyophilized, and stored in the refrigerator, then *P. florida* extract was prepared in different doses (4).

In vivo *administration of* P. florida

Seven test groups of Balb/c mice (five animals/group) were treated with different doses of *P. florida* for 14 days. Four groups received i.p. injection of 10, 20, 50, or 100 mg/kg/day of *P. florida* extract, whereas three others received oral administration of 200, 500, or 1000 mg/kg/day using a feeding tube. The control group received the same volume of normal saline by i.p. injection.

DTH

DTH response was evaluated by priming mice with 1×10^8 sheep red blood cell (SRBC) injected subcutaneously on the back in day 0. The treatments were continued once a day for 2 weeks. Then, the sensitized animals were challenged with 1×10^8 SRBC injected subcutaneously on the left hind footpad in day 14. The increase in the footpad thickness was monitored 24 h after footpad injection using a Mauser dial caliper (Germany). The results expressed an average increase in the footpad thickness which was calculated using the following formula (11,12):

$$\frac{\text{Wright footpad challenged with antigen} - \text{Left footpad challenged with saline}}{\text{Right footpad challenged with antigen}} \times 100$$

Cell viability assay

Cell viability was assessed by the mitochondrial-dependent reduction of 3-(4, 5-Dimethylthiazol-2-yl)—2, 5-diphenyltetrazolium bromide (MTT) to purple formazan. Briefly, MTT powder (Merck, Germany) was dissolved in phosphate-buffer saline (5 mg/mL), filtered, and stored at −20°C until use.

Whole spleen cell suspensions were prepared, freed of red blood cells by treating them with lysis buffer (0.15 M NH4,Cl, 0.01 M KHCO3, and 0.1 mM Na2EDTA, pH 7.4). The spleen cells were incubated (10^6 cell/mL) in complete RPMI medium in 96 well plates in the presence of ConA for 48 h at 37°C in a humidified 5% CO_2 incubator. After 48 h, 20 μL of MTT solution was added. Then, cells were incubated for four more hours with MTT solution and formazan crystals were extracted in acidic isopropanol (0.04 N HCL). Optical density at 540 nm were measured using a Titertek microplate reader, with acidic isopropanol as the blank reference (Stat-Fax 2100, USA).

Specimen harvesting procedure

After the last DTH response measurement, the mice were killed by diethyl ether. All the animals were subjected to detailed necropsy examination. The inguinal lymph nodes and spleen were removed *in toto* and were examined grossly for the changes in size, shape, color, and texture. Representative pieces of these secondary lymphoid tissues were collected and fixed in 10% buffered formalin solution for histological studies.

Histological examination

After fixation, representative pieces of the secondary lymphoid tissues were processed through a standard paraffin embedding method. Sections of 5 mm thickness were cut and stained routinely with Hematoxylin and Eosin to assess the histological alterations. The histological examination of the slides was carried out blindly by a pathologist who was unaware of the treatment groupings. Multiple sections from each tissue were evaluated

RIGHTSLINK

for degenerative, hyperplasic, atrophic, inflammatory, and neoplastic change.

Statistical analysis

The data were expressed as mean ± SEM of each group. Significance of difference was evaluated with one-way ANOVA, followed by Student's *t*-test to statistically identify differences between the control and treated groups. The level of significance was at a P value < 0.05.

Results

Effect of P. florida *on cells viability*

The viability of spleen cells from mice treated with various doses of *P. florida* extract was measured by MTT assay. Cell viability was altered dose and route dependently following *P. florida* extract treatment. As it is shown in Figure 1, the viability of spleen cells from mice treated with i.p injection of 10, 20, or 50 mg/kg/day of *P. florida* was significantly decreased ($P < 0.001$). On the other hand, the viability of spleen cells from mice treated with oral administration of 500 or 1000 mg/kg/day of *P. florida* was significantly increased ($P < 0.001$) compared to the control group (Figure 1).

Effect of P. florida *on DTH reaction*

The results indicated that there was no significant alteration in DTH reaction by different doses and routes of *P. florida* in comparison to the control group (Figure 2).

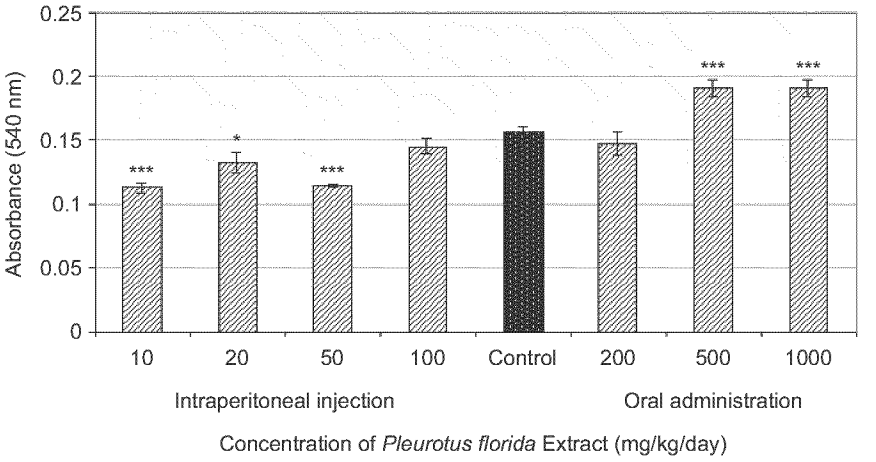

Figure 1. Effect of aqueous extract of *Pleurotus florida* on spleen cells. Intraperitoneal injection of *P. florida* extract in doses of 10, 20, and 50 mg/kg/day significantly decreased cell viability. Oral administration of *P. florida* at the doses of 500 and 1000 mg/kg/day significantly increased cell viability. Each result is the mean ± SEM. $^{*}P < 0.05$, $^{**}P < 0.01$, $^{***}P < 0.001$.

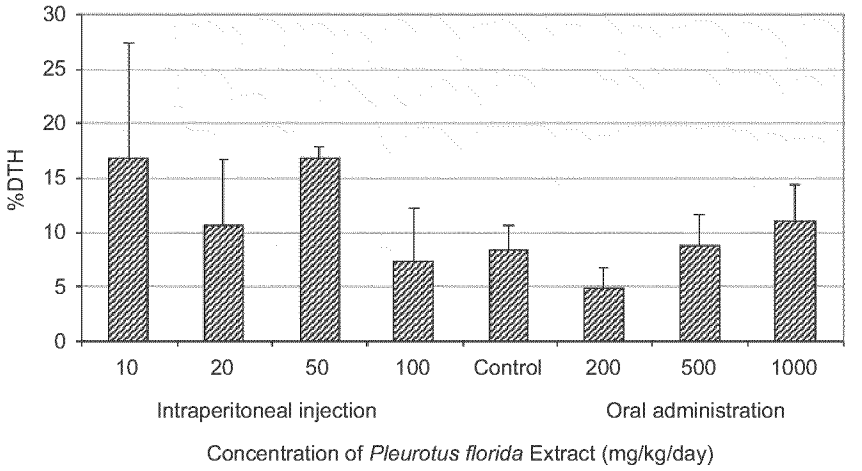

Figure 2. Delayed type hypersensitivity (DTH) response after intraperitoneal injection and oral administration of *Pleurotus florida* extract. As shown, DTH response is not altered following *P. florida* treatment.

Immunopharmacology and Immunotoxicology Downloaded from informahealthcare.com by Colorado State University on 02/10/11
For personal use only.

RIGHTSLINK

Immunopharmacology and Immunotoxicology Downloaded from informahealthcare.com by Colorado State University on 02/10/11
For personal use only.

Gross examination

Macroscopic evaluation of the lymph nodes and spleens of all animals showed no gross changes.

Histological examination of lymph nodes

Different parts of each lymph node including capsule, cortex, paracortex, medulla, subcapsular, cortical, and medullary sinuses were examined microscopically. In all of the microsections of lymph nodes, no abnormal changes were observed in capsule as well as subcapsular, cortical, and medullary sinuses. However, a range of normal to abnormal changes were seen in the cortex, paracortex, and medulla. The most consistent abnormal findings were atrophic and hyperplastic changes in the lymph node cortex in both outer (follicular and interfollicular areas) and inner cortex (the paracortical area) (Figures 3 and 4). In addition, changes representing cell death in germinal centers of lymphatic follicles and evidences of extramedullary hematopoiesis in medulla of lymph nodes were observed in mice of different groups. Microsections of all the lymph nodes showed no inflammatory and neoplastic changes. Lymph nodes of the mice in the control group and some

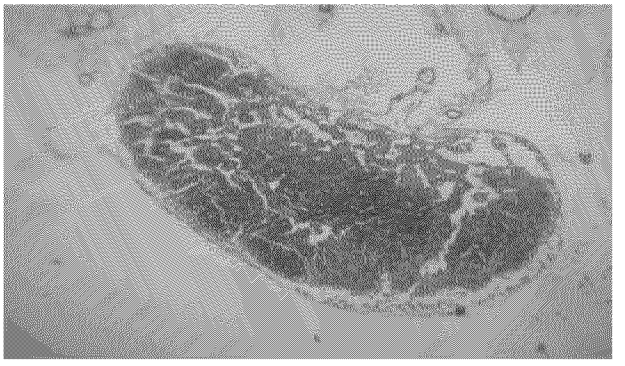

Figure 3. Photomicrograph of mouse lymph node, which received 20 mg/kg of drug parenterally. Figure shows rarefaction of lymphatic tissue and atrophy of lymphatic follicles.Hematoxylin and eosin, ×40.

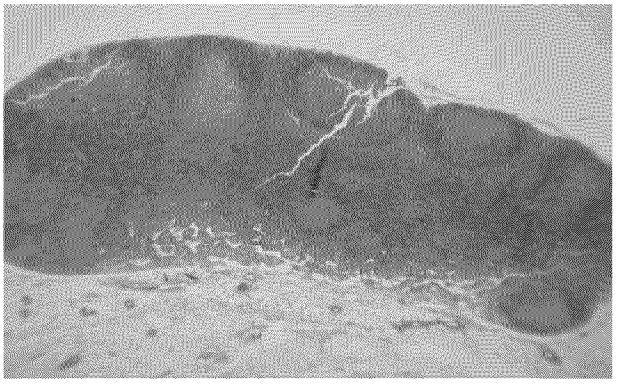

Figure 4. Photomicrograph of mouse lymph node, which received 500 mg/kg of drug orally. Figure shows follicular and interfollicular hyperplasia of lymphatic tissue.Hematoxylin and eosin, ×40.

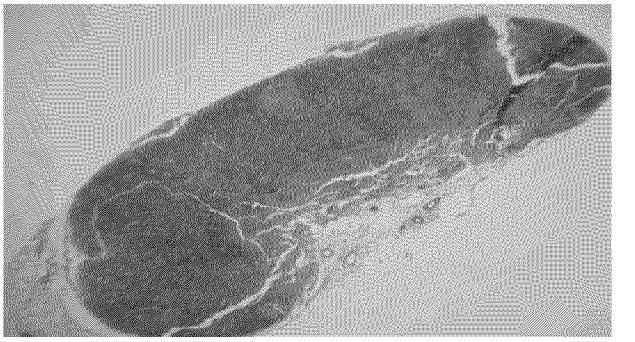

Figure 5. Photomicrograph of mouse lymph node in control group. Figure shows a normal histology.Hematoxylin and eosin, ×40.



Figure 6. Photomicrograph of mouse spleen, which received 20 mg/kg of drug parenterally. Figure shows rarefaction and atrophy of lymphatic tissue (white pulp).Hematoxylin and eosin, ×40.

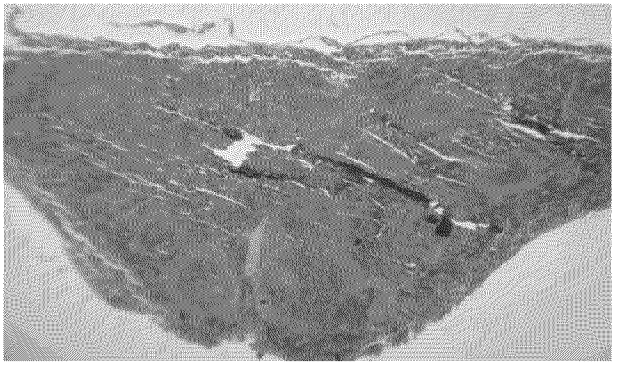

Figure 7. Photomicrograph of mouse spleen, which received 500 mg/kg of drug orally. Figure shows hyperplasia of lymphatic tissue (white pulp).Hematoxylin and eosin, ×40.

RIGHTSLINK

animals of the different test groups exhibited normal histology (Figure 5).

Histological examination of spleens

Different parts of each spleen including capsule, trabeculae, and splenic pulp (white and red pulp) were examined microscopically. In all microsections of spleen no abnormal changes were observed in the capsule and trabeculae. However, a range of normal to abnormal changes was seen in the white and red pulp. The most consistent abnormal findings were atrophic and hyperplastic changes in the lymphatic tissue (white pulp), including periarterial lymphatic sheath (PALS) and lymphatic follicle (Figures 6 and 7). In addition, changes representing cell death in hyperplastic white pulp and evidences of normal extramedullary hematopoiesis in red pulp of the spleens were observed in mice of different groups. Microsections of all spleens showed no inflammatory and neoplastic changes. The Spleens of control group and some animals of different test groups exhibited normal histology (Figure 8).

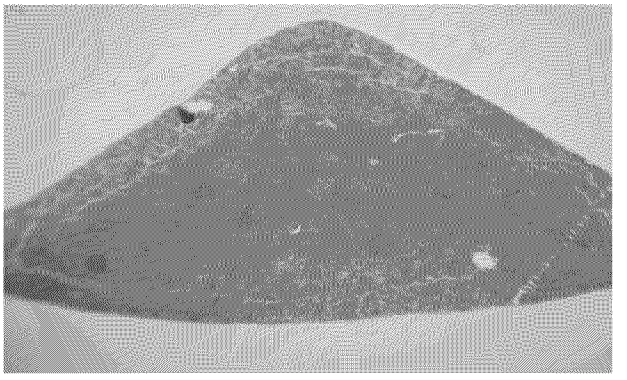

Figure 8. Photomicrograph of mouse spleen in control group. Figure shows a normal histology.Hematoxylin and eosin, ×40.

Histological changes of the lymph nodes and spleens are summarized in Table 1.

Discussion

P. florida is an edible mushroom that is reported to have anti-inflammatory, immunomodulatory and antitumor effects (5,13). *P. florida* mushroom has been shown to modulate the innate immune responses (6,14). In this study, DTH reaction, viability of the spleen cells and histology of secondary lymphoid tissues (lymph node and spleen) were evaluated as parameters of cell-mediated immunity. The results showed that i.p. injection of 10, 20, or 50 mg/kg/day of *P. florida* significantly decreased cell viability; but, oral administration of 500 or 1000 mg/kg/day of *P. florida* significantly increased cell viability of spleen cells in comparison to the control group.

In the previous studies, we investigated the effect of *P. florida* on innate immune responses and considered the effects of *P. florida* on NO production and cell viability of macrophages *in vitro* and *in vivo*. Our *in vitro* findings showed that almost all applied doses of *P. florida* extract significantly increased *in vitro* cell viability and did not show any effects on NO production compared to the control group (4). Our previous *in vivo* findings also indicated that oral administration of *P. florida* extract increased cell viability of macrophages; whereas, i.p. injections did not show any statistical significant effects compared to the control group. Moreover, NO production of macrophages was significantly decreased through i.p. injection and increased following oral administration of *P. florida* (6).

The findings on spleen cells viability in this study are in consistent with our previous work which showed significant induction in macrophages viability following oral administration of *P. florida* (6). In addition, both studies showed that oral administration of *P. florida* with higher doses caused more stimulation in macrophages and spleen cell viability.

Table 1. The effect of different doses of *Pleurotus florida* on splenocytes' viability, delayed type hypersensitivity, and histological changes in the lymph nodes and spleen.

Group	Viability of spleen cells	DTH	Lymph node histology	Spleen histology
10 mg/kg i.p injection	0.11252	16.9369	Atrophy of lymphatic tissue	Normal histology
20 mg/kg i.p injection	0.132333	10.71	Atrophy of lymphatic tissue	Atrophy of lymphatic tissue (white pulp)
50 mg/kg i.p injection	0.11415	17	Atrophy of lymphatic tissue	Normal histology
100 mg/kg i.p injection	0.14488	7.35	Atrophy of lymphatic tissue	Normal histology
Control	0.15604	8.33	Normal histology	Normal histology
200 mg/kg oral administration	0.14728	4.87	Hyperplasia of lymphatic tissue	Exaggerations of normal histology
500 mg/kg oral administration	0.19136	8.8	Hyperplasia of lymphatic tissue	hyperplasia of lymphatic tissue(white pulp)
1000 mg/kg oral administration	0.19085	11.05	Exaggerations of normal histology	normal histology

Immunopharmacology and Immunotoxicology Downloaded from informahealthcare.com by Colorado State University on 02/10/11
For personal use only.

RIGHTSLINK

Histological studies also confirmed the results of spleen cells viability. It was revealed that i.p injection of different doses of *P. florida* extract caused atrophic changes in the lymph node cortex in both outer (follicular and interfollicular areas) and inner (the paracortical area or thymic-dependent zone). Similar changes were also detected in the spleen lymphatic tissue (white pulp), including PALS, a thymic dependent zone similar to the inner cortex of lymph node, and lymphatic follicle after i.p injection of 20 mg/kg of *P. florida*. However, the lymphatic tissues of lymph nodes and spleens showed hyperplasia or exaggerations of normal histology in mice treated with oral administration of *P. florida*.

There was no significant alteration in DTH reaction by different doses and routes of *P. florida*. Although DTH is a typical *in vivo* manifestation of the cell-mediated with T cell activation (15) but it is not as a sensitive test.

To our knowledge, the *in vivo* effects of *P. florida* extract on cellular immune response including DTH reaction, spleen cell viability, and histology of secondary lymphoid tissues has not yet been reported.

In an *in vitro* study conducted by Roy et al., it has been reported that 20 μg/mL of a polysaccharide isolated from *P. florida* significantly increased splenocyte proliferation (5). Although we did not evaluate the *in vitro* effect(s) in the present study, this result is in agreement with the effect of oral treatment in our study.

Regarding usage of this fungus as an edible mushroom, critical considerations should be undertaken in the evaluation of its beneficial or harmful effects in different doses and route of administration. On the other hand, the controlled manipulation of immune response by pharmacological means is also a highly sought goal of clinicians for application of immunomodulator to patients with infectious diseases, cancer, or immunodeficiency disorders where immunomodulation may be of value.

In conclusion, the results of this study revealed that not only doses but also way of treatment is important in the immunomodulatory effects of *P. florida*. The oral administration could increase cell-mediated immunity responses, while some i.p. injections could decrease it. This finding needs to be more investigated with other concentrations and in various models of the diseases.

Declaration of interest

The authors report no conflicts of interest. The authors alone are responsible for the content and writing of the paper.

References

1. Borchers, A.T., Keen, C.L., Gershwin, M.E. Mushrooms, tumors, and immunity: an update. Exp. Biol. Med. (Maywood) 2004, 229, 393–406.
2. Rajewska, J., Balasinska, B. [Biologically active compounds of edible mushrooms and their beneficial impact on health]. Postepy. Hig. Med. Dosw. (Online) 2004, 58, 352–7.
3. Jose, N., Janardhanan, K.K. Antioxidant and antitumor activity of *Pleurotuus florida*. Current. Science. 2007, 9, 941–943.
4. Ghazanfari, T., Yaraee, R., Farahnejad, Z., Hakimzadeh, H., Jamali, D., Danialy, F. *In vitro* effect of *Florida Pleurotus* on Macrophage cell viability and Nitric Oxide production. Food and Agricultural Immunology. 2009, 20, 105–110.
5. Roy, S.K., Das, D., Mondal, S., Maiti, D., Bhunia, B., Maiti, T.K., Islam, S.S. Structural studies of an immunoenhancing water-soluble glucan isolated from hot water extract of an edible mushroom, *Pleurotus florida*, cultivar Assam Florida. Carbohydr. Res. 2009, 344, 2596–601.
6. Ghazanfari, T., Yaraee, R., Farahnejad, Z., Rahmati, B., Hakimzadeh, H. Macrophages activation and nitric oxide alterations in mice treated with *Pleurotus florida*. *Immunopharmacol Immunotoxicol.* 2010, 32, 47–50.
7. Chakraborty, T.K., Das, N., Sengupta, S., Mukherjee, M. Accumulation of a natural substrate of laccase in gills of *Pleurotus florida* during sporulation. Curr. Microbiol. 2000, 41, 167–71.
8. Jose, N., Ajith, T.A., Janardhanan, K.K. Methanol extract of the oyster mushroom, *Pleurotus florida*, inhibits inflammation and platelet aggregation. Phytother. Res. 2004, 18, 43–6.
9. Ajith, T.A., Janardhanan, K.K. Indian Medicinal Mushrooms as a Source of Antioxidant and Antitumor Agents. J. Clin. Biochem. Nutrit. 2007, 40, 157–162.
10. Rout, D., Mondal, S., Chakraborty, I., Pramanik, M., Islam, S.S. Chemical analysis of a new (1->3)-, (1->6)-branched glucan from an edible mushroom, *Pleurotus florida*. Carbohydr. Res. 2005, 340, 2533–9.
11. Ebtekar, M., Hassan, Z.M. Effect of immunomodulators pyrimethamine and cimetidine on immunosuppression induced by sulfur mustard in mice. Int. J. Immunopharmacol. 1993, 15, 533–41.
12. Ghazanfari, T., Hassan, Z.M., Ebrahimi, M. Immunomodulatory activity of a protein isolated from garlic extract on delayed type hypersensitivity. Int. Immunopharmacol. 2002, 2, 1541–9.
13. Santos-Neves, J.C., Pereira, M.I., Carbonero, E.R., Gracher, A.H., Gorin, P.A., Sassaki, G.L., Iacomini, M. A gel-forming beta-glucan isolated from the fruit bodies of the edible mushroom *Pleurotus florida*. Carbohydr. Res. 2008, 343, 1456–62.
14. Moncada, S. Nitric oxide: discovery and impact on clinical medicine. J. R. Soc. Med. 1999, 92, 164–9.
15. Tu, J., Sun, H.X., Ye, Y.P. Immunomodulatory and antitumor activity of triterpenoid fractions from the rhizomes of Astilbe chinensis. J. Ethnopharmacol. 2008, 119, 266–71.

Immunopharmacology and Immunotoxicology Downloaded from informahealthcare.com by Colorado State University on 02/10/11
For personal use only.

RIGHTSLINK