

Effect of Hydroalcoholic Extract of *Hypericum Perforatum L.* Leaves on Ethylene Glycol-Induced Kidney Calculi in Rats

Mohsen Khalili,¹ Mohammad Reza Jalali,² Mohammad Mirzaei-Azandaryani³

¹Department of Physiology, Medicinal Plant, School of Medicine, Shahed University of Medical Sciences, Tehran, Iran

²Department of Pathology, School of Medicine, Shahed University of Medical Sciences, Tehran, Iran

³Shahed University Student Research Committee (SHUSRC), School of Medicine, Shahed University of Medical Sciences, Tehran, Iran

Corresponding Author:

Mohammad Mirzaei-Azandaryani, MD
Department of Physiology, Medicinal Plant, School of Medicine, Shahed University of Medical Sciences, Tehran, Iran

Tel: +98 21 8896 4792
Fax: +98 21 8896 6310
E-mail: mohammadmirzaei89@yahoo.com

Received December 2010
Accepted June 2011

Purpose: To investigate the effects of the hydroalcoholic extract of *Hypericum perforatum* (*H. perforatum*) leaves on the kidney calculi in rats.

Materials and Methods: Fifty-two Wistar male rats were randomly divided into 4 groups: Groups 2, 3, and 4 received ethylene glycol (EG) 1% + ammonium chloride (0.5%)-added drinking water as a stone inducer. The *H. Perforatum* solution was fed at the same time of EG application and was repeated once for two days until the end of the experimental period. Group 1 (control; n = 10) was provided free access to food and normal drinking water. Group 2 (EG; n = 12) received EG-ammonium chloride-added drinking water and was fed with normal chow. Groups 3 and 4 (n = 15), as EG-treatment groups, received *H. Perforatum* in low (300 mg/kg) and high (500 mg/kg) doses, respectively. After 28 days, the kidneys were removed and prepared for histologic evaluation of calcium oxalate deposits.

Results: Urine level of free calcium in groups EG and EG + *H. perforatum* (300 mg/kg) and phosphorous in EG + *H. perforatum* (500 mg/kg) significantly decreased compared to controls ($P < .01$; $P < .05$; and $P < .05$, respectively). Treatment of the rats with high dose of *H. Perforatum* (500 mg/kg) markedly reduced decremating effect of EG on serum level of free calcium ($P < .05$). Histological experiments showed that chronic feeding of *H. perforatum* (300 and 500 mg/kg, orally) could significantly reduce the size and number of calcium oxalate deposits in EG group.

Conclusion: Chronic treatment of rats with hydroalcoholic extract of *H. perforatum* reduced the size and number of calcium oxalate deposits in EG-induced calculi.

Keywords: hypericum perforatum, kidney calculi, ethylene glycol, calcium oxalate

INTRODUCTION

Urinary stone is a prevalent disorder in the urinary system.⁽¹⁾ Genetics, low activity, and diet are the most common factors that could lead to calculi formation by high saturation of calcium and production of calcium oxalate (CaOx) crystals in the kidney.^(2,3) Calcium oxalate and calcium phosphate are the most common kidney stones⁽⁴⁾ and may cause various adverse effects, such as obstruction, infection, hemorrhage, and pain resulted from passage of stones in the urinary tract system.⁽⁵⁾

Unfortunately, chemical drugs for prevention or treatment of the kidney stones could not successfully dissolve the problem. Meanwhile, if laser therapy as a cost-effective procedure is used for disruption of calculi, many severe complications may yield. Therefore, the wisely clinical method for prevention, disaggregation, or disruption of calculi is the usage of a safe, cheap, and with low side effects medication, like medicinal plants.

Hypericum perforatum L., commonly known as St. John's Wort (SJW), is a worldwide herb, which is especially grown in Iran, India, China, Turkey, and some other countries.⁽⁶⁾ The most common SJW preparations used are hydroalcoholic extracts of the aerial portion of the plant that contain at least ten different kinds of biochemical compounds.⁽⁷⁾ The essential and active ingredients of this herb include hypericin, hyperforin, and flavonoids, for which favorable effects have been reported.^(8,9) Many studies show that SJW could relieve mild to moderate forms of depression.⁽¹⁰⁾ Furthermore, antioxidant,⁽¹¹⁾ urinary system relaxant effects,⁽¹²⁾ and inhibition of calcium crystallization in the urinary system have been reported.⁽¹³⁾ The present study has experimentally evaluated the effect of SJW extract on ethylene glycol-induced CaOx crystallization in rat model.

MATERIALS AND METHODS

Animals

Fifty-two adult male Wistar rats (260 to 290 g)

were procured from Pasteur Institute in Tehran, Iran. At first, the animals were housed three to four per cage in a temperature-controlled colony room under a 12 h light/dark cycle. Thereafter, they were given free access to water and kept at 80% to 85% of their free-feeding body weight throughout the experiment.

This study was conducted in accordance with the policies set forth in the Guide for the Care and Use of Laboratory Animals (NIH) and those in the Research Council of Shahed University of Medical Sciences.

Preparation of Plant Hydroalcoholic Extract

Hypericum perforatum (*H. perforatum*) was provided from the local market and was scientifically identified by the department of Botany of Shahed University. The hydroalcoholic extract was prepared as described elsewhere.⁽¹⁴⁾

Experimental Procedure

Ethylene glycol (EG) is an effective renal CaOx inducer in the rats. This component in the body is broken down to some organic acids, especially oxalic acid, which precipitates as CaOx crystals in the kidney. However, concomitant administration of ammonium chloride (0.05%) with EG (1%) could mask the metabolic acidosis induced by EG application solely.

In the present study, the animals were randomly divided into four groups. Groups 2, 3, and 4 received EG 1% + ammonium chloride (0.5%)-added drinking water throughout the entire experimental period (4 weeks). The *H. Perforatum* solutions were fed by gastric gavage at the same time of EG application and repeated once for two days till the end of the experimental period. Group 1 (control group; n = 10) was provided free access to food and normal drinking water. Group 2 (EG group; n = 12) received EG + ammonium chloride-added drinking water and was fed with normal chow. Groups 3 and 4 (n = 15 in each

Table 1. Biochemical data of rats at baseline.

	Baseline data, mmol/dL	Group 1 Control (n = 10)	Group 2 EG (n = 12)	Group 3 EG + HP (low dose) (n = 15)	Group 4 EG + HP (high dose) (n = 15)
Urine level	Phosphorus	117.15 ± 21.20	120.00 ± 15.90	145.00 ± 21.14	115.75 ± 26.60
	Free calcium	51.10 ± 9.3	54.66 ± 10.10	44.02 ± 12.77	38.22 ± 12.27
	Magnesium	113.16 ± 15.17	127.00 ± 13.14	131.75 ± 24.25	139.50 ± 18.22
	Sodium	125.25 ± 8.11	112.00 ± 4.58	111.00 ± 3.71	114.75 ± 7.98
	Potassium	55.50 ± 6.28	63.66 ± 3.18	59.00 ± 7.07	72.25 ± 7.33
Serum level	Phosphorus	8.85 ± 0.70	9.85 ± 0.94	9.53 ± 0.84	8.31 ± 0.45
	Free calcium	11.24 ± 0.11	10.93 ± 0.23	11.10 ± 0.23	11.43 ± 0.35
	Magnesium	2.21 ± 0.43	2.71 ± 0.50	2.78 ± 0.32	2.49 ± 0.28
	Sodium	150.51 ± 1.21	152.33 ± 1.45	151.50 ± 1.32	149.50 ± 0.95
	Potassium	6.35 ± 0.73	6.93 ± 0.88	7.10 ± 0.07	6.97 ± 0.08

EG indicates ethylene glycol; and HP *Hypericum perforatum*.
Data are expressed as mean ± standard error.

group) as EG-treatment groups received *H. Perforatum* in low (300 mg/kg) and high (500 mg/kg) doses, respectively.

Serum and Urine Analysis

At the beginning and end of the experiment, the 24-h urine samples were collected. For this purpose, each rat was individually kept in a metabolic cage for 24 h and its urine was reserved.

The blood serum was obtained for biochemical analysis at baseline and at the 4th week. Blood was collected from retro-orbital plexus by capillary tube at the beginning and from the heart following anesthesia, at the end of the experiments.

Laboratory examination included measurement of free calcium, phosphorus, magnesium, potassium, and sodium.

Evaluation of the Severity of Renal Crystal Deposition

At the end of the experiment after blood sample collection, the rats were killed by carbon dioxide inhalation. Thereafter, the right and left kidneys were removed from the body and weighed. The kidneys were kept in formalin⁽¹⁰⁾ and then blocked by paraffin for histological processing. The sagittally right and left kidney sections in 5 µm were prepared by microtome and then the slides were stained by Hematoxylin and Eosin.

Finally, a light microscope was used in order to examine the presence of crystal depositions in histological sections. For this purpose, aggregation of CaOx deposits were counted in 10 microscopes filed and expressed as mean ± standard error for each group. For accuracy in counting of CaOx deposits, we hypothetically divided each sagittal renal specimen into 10 equal-square size regions by five virtual lines, and then randomly in each region, one microscope field was counted, in addition to 10 microscope fields in each sagittal section.

Table 2. Effect of *H. Perforatum* on urine and serum biochemical data in rats.^{†‡}

	Baseline data, mmol/dL	Group 1 Control (n = 10)	Group 2 EG (n = 12)	Group 3 EG + HP (low dose) (n = 15)	Group 4 EG + HP (high dose) (n = 15)
Urine level	Phosphorus	114.11 ± 19.2	117 ± 13.9	125 ± 18.14	95.75 ± 16.65 ^{a*}
	Free calcium	48.12 ± 08.30	29.54 ± 9.14 ^{a**}	34.30 ± 11.67 ^{a*}	41.32 ± 9.21
	Magnesium	110.13 ± 14.14	147 ± 12.12 ^{a*}	141.75 ± 14.2 ^{a*}	139.5 ± 18.22 ^{a*}
	Sodium	118.20 ± 06.11	111.78 ± 7.58	116.5 ± 3.48	112.75 ± 3.68
	Potassium	47.70 ± 05.32	68.25 ± 4.75	64.31 ± 2.27	66.25 ± 5.58
Serum level	Phosphorus	9.75 ± 0.90	6.89 ± 1.68 ^{a*}	8.14 ± 0.45	8.35 ± 0.28
	Free calcium	10.72 ± 0.41	6.6 ± 0.24 ^{a**}	5.1 ± 0.33 ^{a*}	9.3 ± 0.43 ^{b*}
	Magnesium	2.81 ± 0.41	3.38 ± 0.15	3.39 ± 0.06	2.95 ± 0.17
	Sodium	148.81 ± 2.21	150.75 ± 2.13	151.66 ± 1.66	151.25 ± 1.1
	Potassium	7.45 ± 0.92	6.75 ± 0.26	7.12 ± 0.06	6.90 ± 0.2

[†] EG indicates ethylene glycol; and HP, *Hypericum perforatum*.

[‡] Data are expressed as mean ± standard error.

^a and ^b show significant group compared to normal and EG groups, respectively.

* $P < .05$ and ** $P < .01$.

Data Analysis

One-way ANOVA and post-hoc Tukey tests were used for analysis of serum and urine parameters. The non-parametric Kruskal-Wallis test and Mann-Whitney *U* test were used for comparison of CaOx deposits. *P* values of less than .05 were considered statistically significant.

RESULTS

Biochemical Analysis

Data analysis showed no significant differences in baseline biochemical parameters among control and treatment groups (Table 1). Furthermore, there were no differences in serum and also urine levels of phosphorus, free calcium, magnesium, sodium, and potassium at the beginning of the study.

In Table 2, the serum and urine level of mentioned parameters after the experiment are shown. As indicated, urine level of free calcium in groups EG

and EG + low *H. Perforatum* and phosphorous in EG + high *H. Perforatum* significantly decreased compared to controls ($P < .01$; $P < .05$; and $P < .05$, respectively). Application of EG to normal rats have markedly raised the urine level of magnesium ($P < .05$), which could not be changed by administration of *H. Perforatum* (Table 2). The serum levels of phosphorus and free calcium in EG group significantly diminished in comparison to normal rats ($P < .05$ and $P < .01$, respectively). However, treatment of rats with high dose of *H. Perforatum* (500 mg/kg) could markedly reduce decremented effect of EG on serum level of free calcium ($P < .05$; Table 2).

In complementary study, we could not find any body and kidney weights gain or loss between control and treatment animal groups (Table 3).

Histological Examination

As Figure 1 shows, no CaOx deposits were found

Table 3. Effect of *H. Perforatum* on the body and kidney weight of rats.^{†‡}

	Group 1 Control (n = 10)	Group 2 EG (n = 12)	Group 3 EG + HP (low dose) (n = 15)	Group 4 EG + HP (high dose) (n = 15)
Body weight gain, g*	175.11 ± 16.22	157.63 ± 23.9	159.14 ± 18.14	166.25 ± 17.65
Right kidney weight, g	1.99 ± 0.31	1.83 ± 0.33	1.66 ± 0.47	1.86 ± 0.18
Left kidney weight, g	1.91 ± 0.5	1.74 ± 0.21	1.79 ± 0.49	1.86 ± 0.21

[†] EG indicates ethylene glycol; and HP, *Hypericum perforatum*.

[‡] Data are expressed as mean ± standard error.

* Body-weight gain is computed as the final body weight of each rat minus the baseline body weight of the same rat.

in control animals. But due to EG application, a high number of calculi (44.55 ± 5.23) appeared in the proximal tubules, loops of Henle, distal tubules, and collecting ducts ($P < .001$). Treatment of the EG group with low and high doses of *H. Perforatum* respectively produced 28.16 ± 4.28 and 21.14 ± 4.53 CaOx deposits, which were 43.91% and 44.07% lower than EG group ($P < .05$).

In addition to decrement of the number of calculi in EG + *H. Perforatum* (low and high doses) groups, we also found a marked reduction in the size of CaOx on the microscopic fields of EG-animals which were treated with *H. Perforatum*

extract (Figure 2).

DISCUSSION

In the present study, we successfully induced CaOx formation in the rat's kidney by adding EG to drinking water, which is in line with other studies.⁽¹⁵⁻¹⁷⁾ We added ammonium chloride to EG drinking water for masking the metabolic acidosis induced by EG-derivative acids, such as glycolaldehyde acid, glycolic acid, glyoxylic acid, and oxalic acid.⁽¹⁸⁾

Our data showed that ethanolic extract of *H. Perforatum* had a preventive effect on CaOx calculus formation in the rat's kidney. The low and high doses of extract also reduced the number of CaOx calculi in the treated group by 43.91% and 44.07%, respectively.

Complementary data indicated a low level of free calcium in urine and serum in EG-group in comparison with control animals. This is because most of the serum or urine calcium was bound with oxalate to form crystals; hence, very little free calcium was detected.

To the best of our knowledge, the present study is the first report on the effect of ethanolic extract of the *H. Perforatum* on the prevention and treatment of CaOx kidney calculus.

The exact mechanisms through which *H. Perforatum* affects CaOx calculi are still under debate.

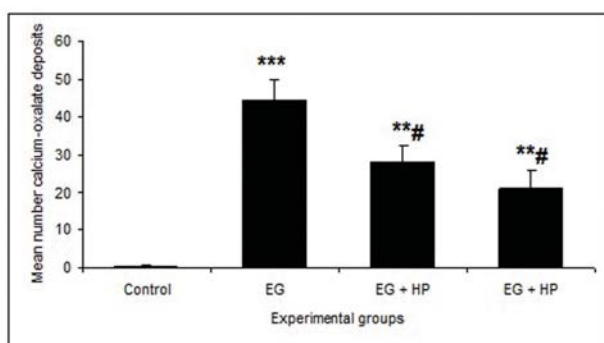


Figure 1. Calcium oxalate deposition in study groups.^{‡‡}

[‡] Bars represent the mean number of calculi in each group.

^{‡‡} EG indicates ethylene glycol; and HP *Hypericum perforatum*.

* and # show difference compared to control and EG groups, respectively. ** $P < 0.01$, *** $P < .001$, and # $P < .05$.

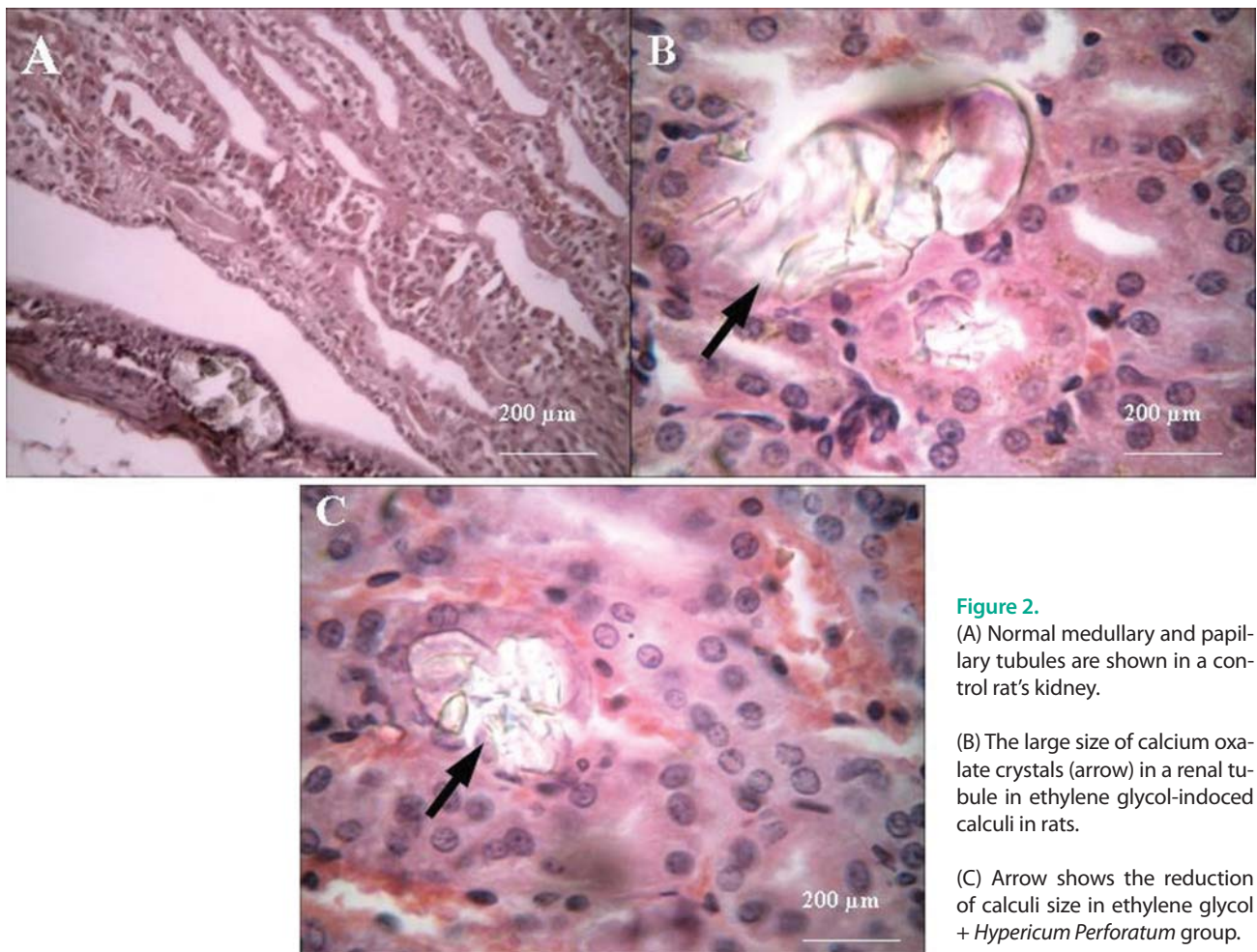


Figure 2.

(A) Normal medullary and papillary tubules are shown in a control rat's kidney.

(B) The large size of calcium oxalate crystals (arrow) in a renal tubule in ethylene glycol-induced calculi in rats.

(C) Arrow shows the reduction of calculi size in ethylene glycol + *Hypericum Perforatum* group.

Calcium oxalate crystals and high levels of oxalate in the nephrons can damage the epithelial cells, and consequently, the cells may produce some products as well as free radicals, inducing heterogeneous crystal nucleation and cause aggregation of crystals.⁽¹⁹⁾

H. Perforatum has glycoside flavonoids, such as quercetin and quercetin-3.^(20,21) Several studies have reported that flavonoides, especially quercetin, have anti-inflammatory and antioxidant effects.⁽²²⁻²⁴⁾ Therefore, it is speculated that *H. Perforatum* could prevent the formation of CaOx calculi and their disaggregation through its anti-inflammatory and antioxidant mechanisms.⁽²⁵⁾ Furthermore, *H. Perforatum* extract may interfere with the process of epithelial cell damage induced

by crystals.⁽²⁶⁾ The reports about the suppression of each step of CaOx crystal formation, growth, and aggregation in vitro⁽²⁷⁾ are concomitant with the same results in vivo trial in our experiment. Therefore, prevention of crystal nucleus production by *H. Perforatum* can be speculated. The most important protein that plays the role of crystal nucleus is chondroitin sulphate.⁽²⁸⁾ In addition to afore-mentioned mechanisms in the formation of CaOx crystals, the role of bacterial origin, such as nanobacteria, should also be mentioned.⁽²⁹⁾ However, the powerful antibacterial effect of *H. Perforatum* could yield its antilithiatic effect.⁽³⁰⁾ Of notice is the diuretic effect of *H. Perforatum*,⁽³¹⁾ which could help in prevention of calculi.

CONCLUSION

The oral feeding of the alcoholic extract of *H. Perforatum* could diminish the number and size of CaOx crystals produced by EG application in rat's kidney. However, before drawing final conclusion, further studies are needed to replicate our results.

CONFLICT OF INTEREST

None declared.

REFERENCES

1. Ho SZ, Kuo HC. Pathogenesis and epidemiology of urolithiasis. *Tzu Chin Med J.* 2002;14:337–46. .
2. Bushinsky DA, Michalenka AC, Strutz KL, Donahue S, Asplin JR. Effect of bolus and divided feeding on urine ions and supersaturation in genetic hypercalciuric stone-forming rats. *Kidney Int.* 2008;73:423-9.
3. Pak CY, Rodgers K, Poindexter JR, Sakhaee K. New methods of assessing crystal growth and saturation of brushite in whole urine: effect of pH, calcium and citrate. *J Urol.* 2008;180:1532-7.
4. Hall PM. Nephrolithiasis: treatment, causes, and prevention. *Cleve Clin J Med.* 2009;76:583-91.
5. Corley RA, Wilson DM, Hard GC, et al. Dosimetry considerations in the enhanced sensitivity of male Wistar rats to chronic ethylene glycol-induced nephrotoxicity. *Toxicol Appl Pharmacol.* 2008;228:165-78.
6. Henderson L, Yue QY, Bergquist C, Gerden B, Arlett P. St John's wort (*Hypericum perforatum*): drug interactions and clinical outcomes. *Br J Clin Pharmacol.* 2002;54:349-56.
7. Ganzera M, Zhao J, Khan IA. *Hypericum perforatum*-chemical profiling and quantitative results of St. John's Wort products by an improved high-performance liquid chromatography method. *J Pharm Sci.* 2002;91:623-30.
8. Bais HP, Vepachedu R, Lawrence CB, Stermitz FR, Vivanco JM. Molecular and biochemical characterization of an enzyme responsible for the formation of hypericin in St. John's wort (*Hypericum perforatum* L.). *J Biol Chem.* 2003;278:32413-22.
9. Medina MA, Martínez-Poveda B, Amores-Sánchez MI, Quesada AR. Hyperforin: more than an antidepressant bioactive compound? *Life sciences.* 2006;79:105-11.
10. Cervo L, Rozio M, Ekalle-Soppo CB, Guiso G, Morazzoni P, Caccia S. Role of hyperforin in the antidepressant-like activity of *Hypericum perforatum* extracts. *Psychopharmacology (Berl).* 2002;164:423-8.
11. Zheleva-Dimitrova D, Nedialkov P, Kitanov G. Radical scavenging and antioxidant activities of methanolic extracts from *Hypericum* species growing in Bulgaria. *Pharmacogn Mag.* 2010;6:74-8.
12. Capasso R, Borrelli F, Montanaro V, Altieri V, Capasso F, Izzo AA. Effects of the antidepressant St. John's wort (*Hypericum perforatum*) on rat and human vas deferens contractility. *J Urol.* 2005;173:2194-7.
13. Combest W, Newton M, Combest A, Kosier JH. Effects of herbal supplements on the kidney. *Urol Nurs.* 2005;25:381-6, 403.
14. Khalili M, Kiasalari Z, Roghani M, Azizi Y. Anticonvulsant and antioxidant effect of hydro-alcoholic extract of *Cyperus rotundus* rhizome on pentylenetetrazole-induced kindling model in male mice. *J Med Plant Res.* 2011;5:868-77.
15. Lee YH, Chang LS, Chen MT, Chiang H, Huang JK, Huang WC. Characterization of ethylene glycol-induced urolithiasis model in rats. *J Urol ROC.* 1991;2:518-24.
16. Lee YH, Huang WC, Chiang H, Chen MT, Huang JK, Chang LS. Determinant role of testosterone in the pathogenesis of urolithiasis in rats. *J Urol.* 1992;147:1134-8.
17. Lee YH, Tsai JY, Huang JK. Combined use of 30% lactose rich diet and 1% ethylene glycol: a new animal model for study of urolithiasis. *J Urol ROC.* 2000;11:149–54
18. Leth PM, Gregersen M. Ethylene glycol poisoning. *Forensic Sci Int.* 2005;155:179-84.
19. Khan SR, Thamilselvan S. Nephrolithiasis: a consequence of renal epithelial cell exposure to oxalate and calcium oxalate crystals. *Mol Urol.* 2000;4:305-12.
20. Khan AU, Gilani AH, Najeeb ur R. Pharmacological studies on *Hypericum perforatum* fractions and constituents. *Pharm Biol.* 2011;49:46-56.
21. Butterweck V, Jurgenliemk G, Nahrstedt A, Winterhoff H. Flavonoids from *Hypericum perforatum* show antidepressant activity in the forced swimming test. *Planta Med.* 2000;66:3-6.
22. Ahmed MS, El Tanbouly ND, Islam WT, Sleem AA, El Senousy AS. Antiinflammatory flavonoids from *Opuntia dillenii* (Ker-Gawl) Haw. flowers growing in Egypt. *Phytother Res.* 2005;19:807-9.

23. Comalada M, Ballester I, Bailon E, et al. Inhibition of pro-inflammatory markers in primary bone marrow-derived mouse macrophages by naturally occurring flavonoids: analysis of the structure-activity relationship. *Biochem Pharmacol.* 2006;72:1010-21.
24. Nair MP, Mahajan S, Reynolds JL, et al. The flavonoid quercetin inhibits proinflammatory cytokine (tumor necrosis factor alpha) gene expression in normal peripheral blood mononuclear cells via modulation of the NF-kappa beta system. *Clin Vaccine Immunol.* 2006;13:319-28.
25. Itoh Y, Yasui T, Okada A, Tozawa K, Hayashi Y, Kohri K. Preventive effects of green tea on renal stone formation and the role of oxidative stress in nephrolithiasis. *J Urol.* 2005;173:271-5.
26. Yuen JW, Gohel MD, Poon NW, Shum DK, Tam PC, Au DW. The initial and subsequent inflammatory events during calcium oxalate lithiasis. *Clin Chim Acta.* 2010;411:1018-26.
27. Jeong BC, Kim BS, Kim JI, Kim HH. Effects of green tea on urinary stone formation: an in vivo and in vitro study. *J Endourol.* 2006;20:356-61.
28. Michelacci YM, Boim MA, Bergamaschi CT, Rovigatti RM, Schor N. Possible role for chondroitin sulfate in urolithiasis: in vivo studies in an experimental model. *Clin Chim Acta.* 1992;208:1-8.
29. Ma K, Xu QQ, Huang XB, et al. [Analysis and clinical implication of upper urinary tract stone's bacterial spectrum]. *Zhonghua Wai Ke Za Zhi.* 2010;48:293-5.
30. Saddiqe Z, Naeem I, Maimoona A. A review of the antibacterial activity of *Hypericum perforatum* L. *J Ethnopharmacol.* 2010;131:511-21.
31. Izzo AA, Ernst E. Interactions between herbal medicines and prescribed drugs: an updated systematic review. *Drugs.* 2009;69:1777-98.