



Effects of Platelet Rich Plasma (PRP) and Platelet Rich Growth Factor (PRGF®) on the Wound Healing of Distal Part of Limbs in Horses

Omid Moradi¹, Seyyed Mahdi Ghamsari¹, Mohammad Mahdi Dehghan¹,
Reza Sedaghat², Hesameddin Akbarein³

Abstract

Objectives- To evaluate the efficacy of platelet rich- plasma (PRP) and plasma rich-growth factor (PRGF®) on the wound healing on distal aspect of horses limbs.

Design- Experimental study

Animals - Four mixed- breed adult horses, 13 to 21 years of age and weighting 381 ±85 kg

Procedures- The Limbs of each horse were treated with PRP, PRGF®, Silver Sulfa diazin and one limb received no treatment (only washing with normal saline). In this manner, each horse served as its own control. Latin square was selected as wound distribution model.

Results- There were significant differences between epithelialization, percent of contraction, granular tissue formation, granular tissue surface situation, wound exudation, inflammation severity and angiogenesis in PRP and PRGF® groups, but there were no significant differences between wound surface area, inflammation expansion and fibroplasia.

Conclusion and Clinical Relevance- Due to special trait of healing at distal aspect of horse limb which exuberant granulation tissue can cause dilation, use of PRP and PRGF® to accelerate wound healing at this region are not recommendable.

Key words: PRP, PRGF®, Wound healing, horse, Growth factor.

Introduction

Horses frequently suffer from traumatic wounds and healing of these wounds takes longer and complicated compared to other species¹. Delayed and complicated wound healing causes significant wastage, so many horses will not stay in ideal athletic conditions.² Many factors have been incriminated in problematic wound repair in horse, including poor blood supply, inefficient inflammatory response to trauma, persistent upregulation of profibrotic growth factors, and a disparity between collagen synthesis and lysis as well as microvascular occlusions and deficient apoptosis of the cell components of granulation tissue.³

It is known that platelets and the formation of a provisional matrix play a prominent and likely determinant role in the initiation and maintenance of wound healing. Platelets are naturally activated by exposing to damaged tissue.² Platelets have an important role in healing of damaged tissues by releasing their granular contents, containing anabolic growth factors, into the wound environment. They initiate, propagate and maintain healing process. These growth factors include Platelet Derived Growth Factor (PDGF), Transforming Growth Factor (TGF), Vascular Endothelial Growth Factor (VEGF) and etc which stimulate progenitor cell localization to a wound, fibroblast expansion and wound matrix.^{4,5} In concern with the provisional matrix or scaffolding, growth factors initiate and propagate wound healing.⁶

Platelet Rich Plasma (PRP) and Platelet Rich Growth Factor (PRGF®) are two autologous products which have multiple cytokines release from platelet alpha granules. It was hypothesized that by increasing the concentration of mediators present in the wound bed via the addition of PRP or PRGF®, the acute inflammatory response might be enhanced and consequently accelerate or improve wound repair.^{7,2,8}

¹Department of Clinical Sciences, Faculty of Veterinary Medicine, University of Tehran, Tehran, Iran.

²Department of Pathobiology, College of Medicine, Shahed University, Tehran, Iran.

³Department of Epidemiology and Zoonoses, Faculty of Veterinary Medicine, University of Tehran, Tehran, Iran.

Address all correspondence to Dr. Seyyed Mahdi Ghamsari, (DVM, DVSc), E-mail: ghamsari@ut.ac.ir

Materials and methods

Animals

Four mixed-breed adult horses, 13 to 21 years of age and weighting (Mean±S.D) 381 ±85 kg were used. Horses were free of any clinically detectable medical disorder, received tetanus prophylaxis prior to the study, and were feeding with hay daily. Horses were examined daily for sign of discomfort, lameness, and bandage slippage.

Surgical procedures

Horses were tranquilized by intravenous (IV) administration of xylazine (1.1 mg/kg) and were anesthetized by administration of Ketamin (2.2 mg/kg). Surgical sites (metacarpus and metatarsus) were prepared, and three rectangular shape (3×2cm) full-thickness wound were created with minimum 2 cm apart on the dorsolateral surface of each metacarpus and metatarsus (n=48 wounds). All limbs were bandaged in a layered fashion to control bleeding; Non adherent permeable dressing was secured with sterile conforming cotton gauze that was held in place with elastic bandage and adhesive tape at extremities. A layered bandage was applied 24 hours prior to commencing treatment. The bandage is changed twice a week.

Preparation of autologus PRP

PRP was prepared by manual method which prescribed with Monterio et al.³ Sixty ml blood samples were collected through a single jugular venipuncture with an 18-gauge needle into syringe which contains 7.5 ml citrated dextrose anticoagulant. Blood samples were centrifuged at 72×g for 15 minutes to achieve separation of cell layers. Red blood cells were isolated from overlying buffy coat and plasma by the plug within the patented platelet sequestration tubes. This fluid centrifuged again at 100×g for 5 minutes. This procedure produced approximately thirty ml PPP (platelet poor plasma) and six ml PRP. This PRP, is activated by adding 50 μ l/ml CaCl₂ (MERK®) and 100 μ l/ml bovine thrombin (SIGMA-ALDRICH®).^{9,10,11}

Preparation of autologus PRGF®

Due to BTi® factory manual protocol 60 ml blood samples are transported to special tubes which contain anticoagulant fluid (citrate) and then centrifuged with Bti PRGF® centrifuge (580 g for 8 minutes). 1/3 Upper buffy coat fluid was isolated and injected to another tubes and PRGF® activator ampoule (50 μ l/ml CaCl₂) mixed with it. These tubes were put in registered BTi® incubators for 5 minute to create a PRGF® gel.

Experimental Design

The Limbs of each horse were treated with PRP, PRGF®, Silver Sulfadiazin and one limb received no treatment. Latin square design was selected as wound distribution model.

Wounds were identified as A,B,C from proximal to distal locations on the limb. Two ml of activated PRP and two ml of PRGF® were prepared for each wound/horse and applied at wound surface. All wounds were dressed with non-adhesive strip dressing.

Geometric assessment

After each bandage changing, wounds were cleaned with normal saline solution and sterile gauze and photographed with a digital camera alongside a 2 dimensional scale to measure the wound surface area. Exuberant granulation tissue was sharply excised with scalpel when elevated at least 2 mm above skin edges. Total wound area, epithelialization and percent of contraction were measured with sigma scan software.¹²

Clinical assessment

After changing each bandage at day 10, 20 and 30 wound healing quality was assessed and scaled (0 – 3) as follow:

- Granulation tissue formation:

0= lower to equal to skin surface, 1= one to 2 mm above the skin surface, 2= two to 3mm above the skin surface, 3= more than 3mm upper than skin surface

- Granular tissue surface situation (regularity, irregularity):

0= smooth and regular, 1= a few irregularity, 2= irregular, 3= severely irregular

- Wound exudation situation:

0= without exudate, 1= little exudate, 2= moderate exudate, 3= sever exudate

Histopathological evaluation method

Tranquilization was performed before biopsy taking. Specimens were obtained with a 7 mm diameter biopsy punch from wound A at 10th days, wound C at 20th days and wound B 30th days after beginning of the study. Specimens used for histopathological study were taken from the center of the wounds and were fixed in neutral-buffered 10% formalin, processed in paraffin blocks, sectioned for histological examination, and stained with H&E and Masson Trichrom by use of standard procedures.¹³

An observer, blinded to the treatment groups, evaluated inflammation expansion, Inflammation severity, angiogenesis, fibroplasia, and complete wound healing which were scaled in 0-3 by defined criteria. These criteria were included¹⁴.

Inflammation expansion:

0= No observation of inflammatory cells.

1= Observing inflammatory cells in 1 or 2 microscopic fields.

2= Observing inflammatory cells in 3 or 5 microscopic fields.

3= Observing inflammatory cells in more than 5 microscopic fields.

Inflammation severity:

- 0= No observation of inflammatory cells.
- 1= Observing inflammatory cells with high empty spaces between them.
- 2= Observing inflammatory cells with low empty spaces between them.
- 3= Observing inflammatory cells with almost no empty spaces between them.

Angiogenesis:

- 0= No observation of new blood vessels in 10 microscopic sights (400x).
- 1= Observation average of 1-5 blood vessels in 10 microscopic sights.
- 2= Observation average of 5-10 blood vessels in 10 microscopic sights.
- 3= Observation average of more than 10 blood vessels in 10 microscopic sights.

Fibroplasia:

- 0= Observation of many fibroblasts, no Observation of collagen fibers
- 1= Observation of many fibroblasts and a few collagen fibers in microscopic sights.
- 2= Observation of intermediate fibroblasts and intermediate thick collagen fibers.
- 3= Observation of a few fibroblasts and many thick collagen fibers (collagen bundle)

Complete wound healing:

- 0= Observation of inflammatory cells, no observation of blood vessels, fibroblasts and collagen fibers.
- 1= Contemporary observation of inflammatory cells, blood vessels, fibroblasts and collagen fibers.
- 2= Contemporary observation of blood vessels, fibroblasts and collagen fibers, no observation of inflammatory cells.
- 3= Observation of fibroblasts, thick and compact collagen bundle, no observation of inflammatory cells and blood vessels.

Statistical Analysis

Statistical analyses were done by SPSS software version 16.0. Repeated measures analysis with 95% Confidence Interval was done by General Linear Model (GLM) procedure was used of continuous variables with normal distribution. The Friedman and Mann-Whitney U tests were used to evaluate the ordinal variables. A P-value of less than 0.05 was considered statistically significant.

Results

Geometric findings

No significant difference between wound surface area between groups was seen (P=0.938)
 Significant difference between epithelialization of different days between groups was seen (P=0.001)(Fig.1).
 Significant difference between percent of contraction of different days between groups was seen (p=.011) (Fig.2).

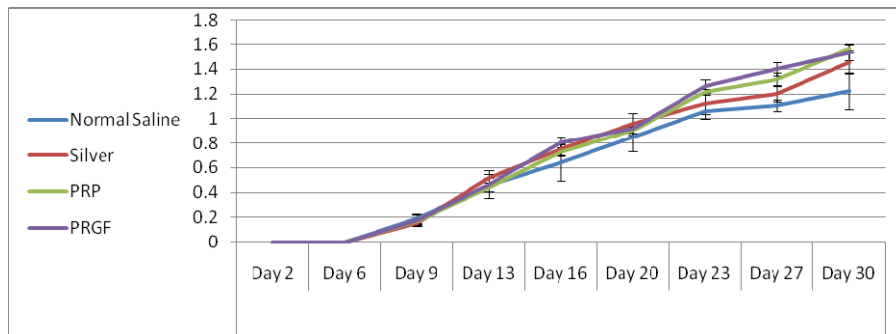


Figure 1- Mean ± Standard deviation of epithelialization at different days.

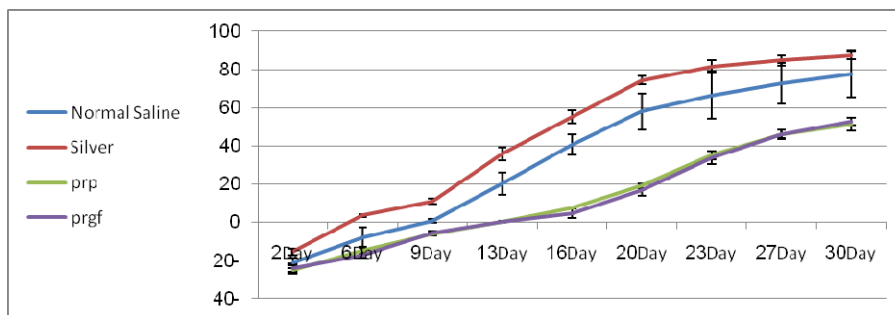


Figure 2- Mean ± Standard deviation of contraction percent at different days.

Clinical findings

Significant difference between granulation tissue formation was seen ($P < 0.001$) (Fig.3, Fig.4)

Significant difference between granular tissue surface situation was seen ($P < 0.001$) (Fig.5).

Significant difference between amount of wound exudates of 4 groups was seen ($P < 0.001$) (Fig.6).



Figure 3- Macroscopic appearance of treated wound 18 days after treatment. Left to right: PRP, PRGF[®], Silver Sulfadiazin, Normal saline groups. Granulation tissue appear exuberant and require to surgical excision at PRP and PRGF[®] groups.

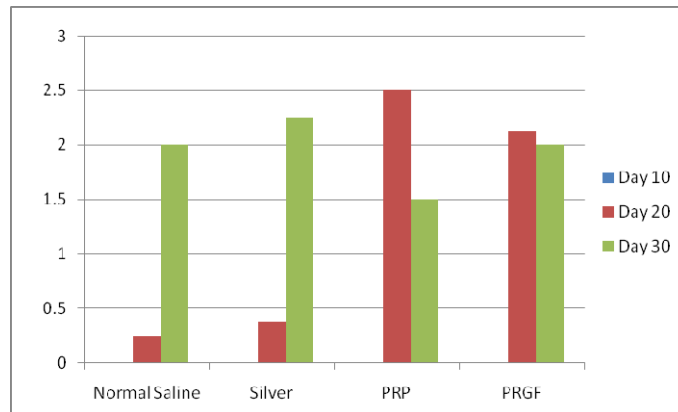


Figure 4- Comparison between granulation tissue formation at days 10,20,30. This parameter at PRP and PRGF[®] significantly more than Normal saline and Silversulfadiazin

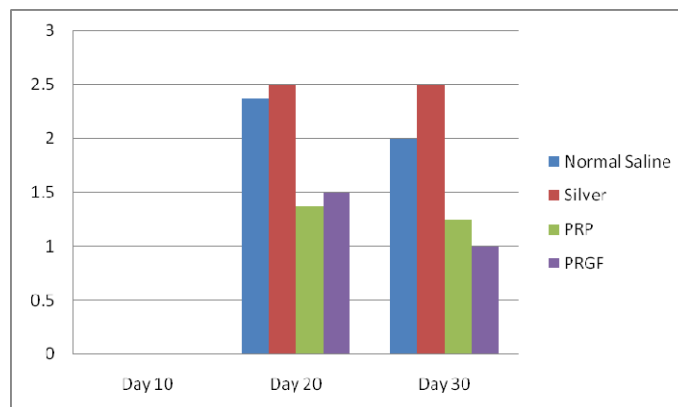


Figure 5- Comparison between granulation tissue surface situation at days 10,20,30. The wound treated with PRP and PRGF[®] significantly have smoother surface than Normal saline and Silver Sulfadiazine

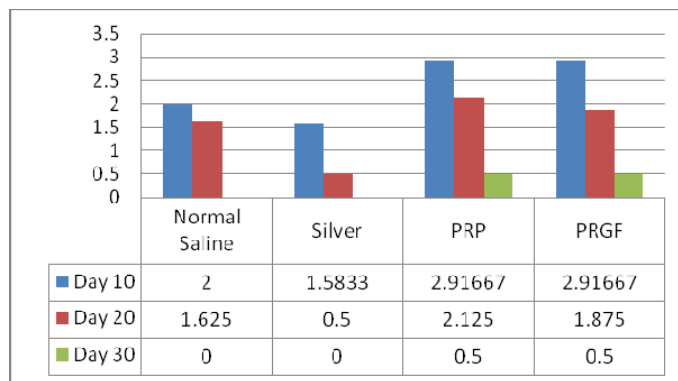


Figure 6- Comparison between wound exudates at days 10, 20, 30. The wound treated with PRP and PRGF® significantly has more exudates than Normal saline and Silver Sulfadiazine groups

Histopathological finding

No significant difference between inflammation expansion of groups was seen (p=0.743).

Inflammation at days 10,20,30 is significantly more severe in PRP and PRGF® groups than 2 other groups (P=0.005), but no difference between PRP and PRGF® groups was seen(P=0.067)

Significant difference between angiogenesis of PRP and PRGF® groups and 2 others groups was seen (P=0.005) but no difference between PRP and PRGF® was seen(P=0.09)

No significant differences was seen in fibroplasia between groups (P=0.234)

No significant difference was seen in complete wound healing between groups (P=0.238).

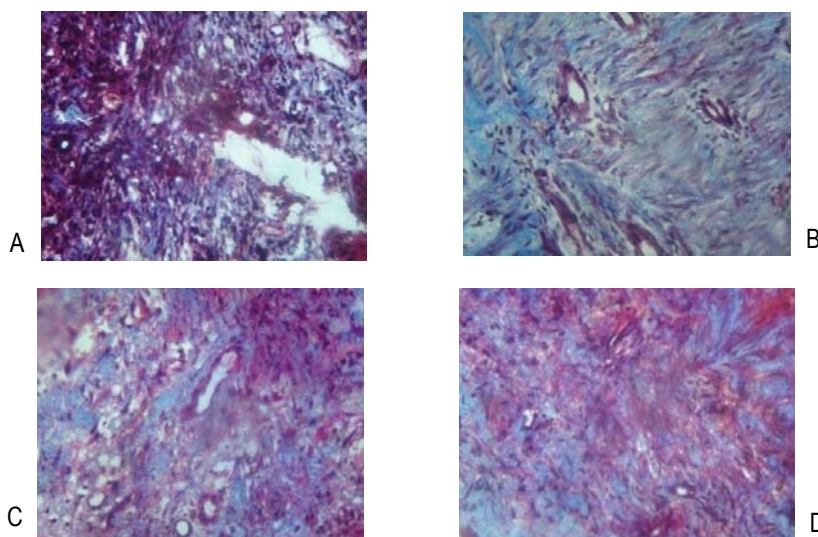


Figure 7 (x400) – Masson-trichrom stain. Day 28. Angiogenesis is sever in PRP(C) and PRGF® (D) than Silver Sulfadiazine (B) and Normal Saline (A) groups.

Discussion

To have a role in haemostasis and wound healing, platelets activate fibrinogen and form a fibrin clot which acts as a tissue sealant. Platelets also play an important role in the future stages of tissue repair. More than 30 growth factors including Platelet Derived Growth Factor(PDGF), Transforming Growth Factor(TGF), Vascular Endothelial Growth Factor(VEGF) and etc were expressed and caused longer lasting effect of activated platelets.²

The ability to repair cutaneous wound following injury is critical for survival. Aging and many kind of diseases such as nutritional and metabolic injuries, alter the effectiveness of the wound-healing process.^{9,15} However healing the wound below the hock or knee in the horse have many serious problem.² This may be due to the poor blood supply thus lower oxygen, lower temperature and imbalance or insufficiency of growth factor.⁵ These factors lead to major impairment of extra cellular matrix and delayed wound healing. Concentration and activation of platelets into a PRP and PRGF® then application

of that as a gel to the wound surface is an effective method for replacing essential growth factors, especially TGF- β_1 and PDGF, at increased concentrations in physiologic balance, thereby creating an environment conducive to wound healing. TGF- β_1 was predicted to be of therapeutic value in the treatment of chronic, non-healing or slow to heal wounds. PDGF improves dermal regeneration, acts to locally migrate or angiogenesis and induces the expression of TGF- β_1 .^{9,7,16} Because TGF- β_1 promotes differentiation and proliferation associated with wound healing and horses have a weak protracted inflammatory response to trauma, it was hypothesized that by increasing the concentration of proinflammatory mediators (especially TGF- β_1) via the topical application of autologous PRP and PRGF[®], the chemotaxis of WBCs would be improved, which would ameliorate debridement and decrease the stimulus for a prolonged inflammatory response, thereby limiting attending fibrosis. Moreover, higher concentration of TGF- β_1 should accelerate the differentiation of fibroblast toward a myofibroblast phenotype, thereby enhancing wound contraction and simultaneously limiting the number of remaining synthetic fibroblasts, consequently, the amount of extracellular matrix deposited in the wound would be decreased.^{1,2,3,9}

PRP and PRGF[®] are obtained by centrifugation of anticoagulated blood. After centrifugation, the separated buffy coat layer, consisting of platelets and white blood cells, forms the PRP and PRGF[®]. Originally a full unit of blood was needed for the preparation, however nowadays preparation from smaller volumes of blood are possible.³

Platelet concentrates can be obtained by at least 3 means: the tube (manual), buffy coat (semi automated), and apheresis (automated) methods.^{17,6} Advantages of tube method are its low cost and minimal technique requirements. The single and double centrifugation tube method is reported to be reliable for concentrating equine platelets and for obtaining potentially therapeutic TGF- β_1 concentration.^{9,2} The PRP preparation method used in this study was simple, easy to perform and rapid. It increased platelet concentration more than 3 fold over concentration in blood and serum.^{17,18}

In contrast to hypothesis topical application of PRP and PRGF[®] to the wound of distal aspect of horse limb, may not accelerate healing. This may be due to follow reasons:

1- Increase at inflammation severity and angiogenesis of PRP and PRGF[®] groups in comparison with other groups. This matter predictable, because amount of growth factor which cause inflammation (PDGF, TGF- β) and angiogenesis (PDGF, TGF- β) in these groups are more than other groups. But prolong acts of these factors cause delaying in healing process.¹⁷

2- Increase in wound exudates: inflammation might cause more exudation and delaying of healing.

3- Excessive development of granulation tissue: many of growth factors have mitogenic stimulator behavior and cause excessive growth of granular tissue. Expansion of granulation tissue above and beyond the wound margins may have physically inhibited epithelial cell migration and mitosis thus delays in healing occurred.¹⁸

Small size of treated wound: previous scientific study showed that this treatment fashion might hold more promise for the management of massive tissue loss (exp: avulsion) and in experimental wound may not performed significant effect.³

In conclusion, the use of PRP or PRGF[®] to accelerate healing of wound at distal aspect of the horse limbs are not considerable, because growth factors produce excessive granulation tissue, inflammation, exudation and they may delay in healing process, this is same to result of Monterio et al reported at 2009.¹⁷ Increase in inflammatory phase can stimulate the formation of hypertrophic scarring, and thus needs to be avoided on superficial defects.¹⁸ Because PRP and PRGF[®] can produce vascularized bed of granulation tissue might promote to take of skin graft, but the influence on re-epithelialization is controversial.³ Knighton et al (1986) have shown enhanced re-epithelialization of chronic lower extremity wounds but the effect of these products on other wound is unknown.¹⁶

References

1. Wilmink J M, Weeren R, Differences in wound healing between horses and ponies: application of research results to clinical approach of equine wounds. *J Clinical techniques in equine practice* 2004;3:123-133.
2. Steven P, Demetris D, Scott AR, What is the platelet rich plasma? *J Operative technique in sport medicine* 2011;19:142-148.
3. Monterio SO, Lepage OM, Theoret CL, The effect of platelet-rich plasma on the repair of wounds on the distal aspect of the forelimb in horses *Am j of veterinary research* 2009;70:277-282.
4. Sanchez A R, Sheridan PJ, Kupp LI, Is platelet-rich plasma perfect enhancement factor? A current review. *Int J oral maxillofacial implants* 2003;18:93-103.
5. Cochrane CA, Freeman KL, Knottenbelt DC, Effect of growth factors on the characteristics of cells associated with equine wound healing and sarcoid formation. *J wound repair regeneration* 1996 7:119-126.
6. Wasterlain AS, Brauna HJ, Dragoo JL, Contents and formulations of platelet-rich plasma. *J Operative techniques in orthopedics* 2012;22:33-42.
7. Roberts AB, Sporn MB, Transforming growth factor- β in the molecular and cellular biology of wound repair. 2nd. New York:Plenum Press, 1996;275-298.
8. Anita E, Sanchez Mikel, Orive G, et al. The potential impact of the preparation rich in growth factors (PRGF[®]) in different medical fields. *J Biomaterials* 2007;28:4551-456.
9. Arguelles D, Carmona JU, pastor J. Evaluation of single and double centrifugation tube method for concentrating equine platelets. *J research veterinary science* 2006;81:237-245.
10. Landesberg R, Burke A, Pinsky D, et al. Activation of platelet-rich plasma using thrombin receptor agonist peptid. *J Oral and maxillofacial surgery* 2005;63:529-535.
11. Zandim BM, de Souza MV, Magalhães PC, et al. ultra structure and morphometry in the platelet-rich plasma of horses. *J Pesq veterinary brasil* 2012;32(1):83-92.
12. Gorin DR, Cordts PR, La Morte Wayne W, The influence of wound geometry on the measurement of wound healing rates in clinical trials. *J Vascular surgery* 1996;23:524-528.
13. Sardari K, Emami MR, Kazemi H, et al., Effects of platelet-rich plasma (PRP) on cutaneous regeneration and wound healing

- in dogs treated with dexamethasone. *J Comparative clinical pathology* 2011;20:155-162.
14. Hadjipour N, Marjani M, Sedaghat R, et al. Histopathological Absorption Trend Comparison between Chromic Catgut Suture Materials Produced by Different Companies in Rabbits. *J Animal and Veterinary Advances* 2008;11:1341-1344.
 15. Nobert P, Wolter Tim, Markowicz M, Platelet-rich plasma in burns. *J burns* 2010;36:4-8.
 16. Knighton DR, Ciresi K, Fiegel VD, et al., Classification and treatment of chronic nonhealing wounds. Successful treatment with autologous platelet derived wound healing factors (PDWHF). *J Ann Surgery* 1986;204:322-330.
 17. Monterio O, Lepage M, Theoret L, The effect of platelet-rich plasma on the repair of wounds on the distal aspect of the forelimb in horses. *Am j of veterinary research* 2009;70:277-282.
 18. Pietrzak WS, Eppley BL, Platelet rich plasma: biology and technology. *J craniofacial surgery* 2005;16:1043-1054.
 19. Carter C A, Jolly DG, Worden S, et al. Platelet-rich plasma gel promotes differentiation and regeneration during equine wound healing. *J Experimental and molecular pathology* 2003;74:244-255.

چکیده

تاثیر پلاسمای غنی از پلاکت (PRP) و پلاسمای غنی از فاکتور رشد (PRGF®) بر التیام زخمهای قسمتهای انتهایی اندامهای حرکتی اسب

دکتر امید مرادی^۱، دکتر سید مهدی قمصری^۱، دکتر محمد مهدی دهقان^۱،
دکتر رضا صداقت^۲، دکتر حسام الدین اکبرین^۳

^۱ گروه آموزشی علوم درمانگاهی، دانشکده دامپزشکی دانشگاه تهران، تهران، ایران
^۲ گروه آموزشی پاتوبیولوژی، دانشکده پزشکی، دانشگاه علوم پزشکی شاهد، تهران، ایران
^۳ گروه آموزشی اپیدمیولوژی و بیماریهای مشترک، دانشکده دامپزشکی دانشگاه تهران، تهران، ایران

هدف - بررسی اثرات استفاده از پلاسمای غنی از پلاکت (PRP) و پلاسمای غنی از فاکتور رشد (PRGF) بر التیام زخمهای قسمتهای انتهایی اندام حرکتی در اسب

طرح - مطالعه تجربی

حیوانات - ۴ راس اسب بالغ سالم

روش کار - در قسمت انتهایی هر اندام حرکتی ۳ زخم ایجاد و درمانهای مورد نظر که شامل PRP، PRGF® و سیلورسولفادیازین بود، روی زخمها قرا داده شد. یک گروه نیز فقط با استفاده از سرم نرمال سالین شستشو داده شدند. توزیع درمانها با استفاده از مدل مربع لاتین انجام پذیرفت به نحوی که در این مطالعه هر اسب به عنوان گروه کنترل خود نیز محسوب شود.

نتایج - تفاوت معناداری بین میزان اپیتلیزاسیون، درصد کانتراکشن، تولید بافت گرانوله، وضعیت سطح بافت گرانوله، میزان ترشح زخم، شدت التهاب و آنژیوژنز در گروههای تحت مطالعه وجود دارد. ولی مابین مساحت زخم، وسعت التهاب و فیبروپلازی گروههای مورد بررسی تفاوت معناداری گزارش نمی شود.

نتیجه گیری و کاربرد بالینی - با توجه به شرایط ویژه التیام در نواحی پائینی اندام حرکتی اسب که در آن رشد اضافی بافت گرانوله یکی از معضلات محسوب می شود، به نظر نمی رسد استفاده از PRP و PRGF® تاثیری در تسریع روند التیام زخمهای این نواحی داشته باشند.

کلیدواژگان - پلاسمای غنی از پلاکت، پلاسمای غنی از فاکتور رشد، التیام زخم، اسب، فاکتور رشد